

Posterior vertebral osteotomy and Ponte osteotomies in surgical treatment of adolescent idiopathic scoliosis type Lenke 1-4

Adelin Ivanov

Acibadem City Clinic Tokuda Hospital, Sofia, Bulgaria
a3ivanoff@gmail.com

Abstract

Introduction

The purpose of the study is to present the results of the application of posterior vertebral osteotomy with Ponte osteotomies (PO) in the operative treatment of adolescent idiopathic scoliosis (AIS), Lenke 1-4. The study encompasses patients with more than 60 degrees Cobb angle rigid deformities in the frontal plane with correction below 40% percents in the bending tests. Patients with both hyperkyphosis reported in the T5-T12 segment and marked hypokyphosis in the same area of the thoracic zone were also included in the study.

Material and methods

The study encompasses 38 patients (men 11, women 27) with adolescent idiopathic scoliosis type Lenke 1-4 and has been conducted in the period 2010-2018. The patients, included in the study, were of the age between 10 and 18 years, average age: 14.2 ± 0.5 .

Results

The following results were reported: Correction at one level osteotomy - 8-11 degrees in kyphosis and less than 5 degrees in the coronal plane; Blood loss at one level osteotomy: 50-95 ml; Time for osteotomy at one level: 19-28 min.

Conclusion

Ponte osteotomy and posterior instrumentation with pedicle screws is an effective and relatively safe surgical method to achieve good sagittal and frontal correction in cases with pronounced and rigid thoracic deformities. The performance of osteotomies is associated with increased blood loss and operative time, but it is of key importance in achieving an important correction of the sagittal disorder in hyper or hypokyphosis cases.

Keywords— adolescent idiopathic scoliosis, Ponte osteotomy, posterior vertebral osteotomy

1 Introduction

AIS is a deformity of the spine in all three planes. The goal of surgical treatment is to achieve sustainable correction of deformities resulting in a balanced spine in the sagittal and frontal plane. The most commonly used technique at present is the posterior vertebral osteotomy with pedicle screws or hybrid techniques with sublaminar bands, which

give good and sustainable results. The pedicle hook techniques used in the past have lower levels of correction and durability. Achieving the desired corrections is related to the mobilization of the instrumented levels. The technique of partial facetectomy to obtain a solid posterior spinal fusion in scoliosis surgery was first described by Hibbs¹ in 1924 and later by Moe². In 1945, Smith-Petersen et al.³ describe a single-level posterior column osteotomy for correction of fixed lumbar flexion deformity in a rigid spine secondary to rheumatoid arthritis and/or ankylosing spondylitis.

In the 1980s, Alberto Ponte et al.⁴, recommended a similar procedure consisting of wide posterior releases, full excisions of the facet joints, and shortening of the posterior column at multiple levels to correct sagittal plane deformity in Scheurmann's kyphosis. Currently, the two types of osteotomies/Smith-Petersen osteotomies and Ponte osteotomies/ are often used as analogous terms-/SRS news March 2014/. Shufflebarger and Clark^{5,6} first described the use of this procedure for correction of lumbar and thoracolumbar adolescent idiopathic scoliosis (AIS) and showed better deformity correction using hooks and pedicle screws. A true Ponte osteotomy can produce distinct mobility in flexion, extension, and rotation, making it justified in the treatment of thoracic deformities, especially scoliosis⁷.

The stages in the implementation of Ponte's operative technique are the following – 1) careful visualization of the bone structures in the area; 2) resection of spinose processes and interspinal ligaments; 3) partial laminectomy and resection of ligamentum flavum; 4) resection of articularis processes. The operative technique is characterized by a mandatory available mobility in the area of the intervertebral disc and an expected correction of about 10°- 15° (1 mm = 1°) on each level. Ponte osteotomies ensure the use of sublaminar wires, which create conditions for a better and more stable correction of the thoracic deformity in the coronal plane without limiting a possible sagittal correction. A cadaveric study on the possibilities after a series of 3 consecutive Ponte osteotomies showed an increased mobility in the three planes - flexion with an increase of 69%, extension with an increase of 56%, rotation with an increase of 65%, lateral bending - without significant changes⁸.

The deformities in patients with AIS, range from flexible, hypokyphotic to rigid and hyperkyphotic curves. Maintaining and restoring thoracic kyphosis is important to keep good lumbar lordosis and prevent flat back and loss of sagittal balance with the age.

Ponte osteotomy is a widely used technique to achieve coronary, rotational, and sagittal correction of large thoracic curves in AIS in combination with pedicle screws, but it is with controversial results.

Shah and colleagues⁹ reported 87 AIS patients with Lenke type 1-4 scoliotic deformities, treated with pedicle screws and Ponte osteotomies. They reported excellent correction in the coronal and sagittal planes, but they did not have a “no Ponte” control group.

Halanski and Cassidy¹⁰ reported the use of Ponte osteotomies to 18 patients with thoracic idiopathic scoliosis (Lenke 1 and 2) and compared the results with 19 patients who underwent inferior facetectomy. They concluded that the Ponte osteotomy group had an increased blood loss and operative time, without significant differences in coronary and sagittal correction.

In the current study, we present a retrospectively collected, one-center database of AIS patients with large rigid thoracic deformities. For all patients the operative treatment was posterior vertebral osteotomy with pedicle screws placed with a free-hand technique, the use of multimodal intraoperative monitoring/MIOM/ and Ponte osteotomies, including wide posterior release, partial laminectomy, resection of the ligamentum flavum and articular processes, and lengthening of the posterior column in hypokyphotic curves, or shortening of the posterior column in cases of hyperkyphosis. The coronal and sagittal curve correction, blood loss at one level of osteotomy, time to perform one level of osteotomy, MIOM signal changes and complications, were evaluated.

2 Material and methods

The study is a retrospective and includes 38 patients who underwent surgical treatment for adolescent idiopathic scoliosis Lenke 1-4 for the period 2010 - 2018 at the Orthopedics and Traumatology Clinic at "Acibadem City Clinic Tokuda Hospital" JSC.

The operative procedures were performed by the Orthopedics and traumatology clinic's team with the participation of anesthesiologists, who were also involved in the MIOM.

The gender distribution of patients is as follows: men - 11, women - 27.

The patients included in the study were aged between 10 and 18 years, average age: 14.2 ± 0.5 .

The following methods were applied:

- 1) Pre-operative assessment of deformities, classification of scoliosis and instrumentation procedure planning.

Numerous clinical signs were reported during the clinical examination:

- ✓ signs of coronal imbalance – shoulder height, shoulder blades, pelvic tilt, limb length
- ✓ signs of sagittal imbalance - kyphosis, lordosis, presence of clinically pronounced positive or negative sagittal balance with impaired posture.
- ✓ signs of rotational deformity - rib hump and degree of expression.

- 2) Data from instrumental studies: standing radiographs - front, profile, left and right bending in supine position, traction.

Cobb angle size, rotation size (Moe-Nach method), kyphosis size, lordosis, lumbar modifier were taken into account. The data from the studies allowed us to determine the scoliotic deformity according to the Lenke's classification and plan the operative procedure. The level of bone maturation according to the Risser classification is also reported on the X-ray. It examines the overall medical status of the patients, – accompanying diseases, blood parameters, functional parameters (especially for those with a high value of Cobb angle), problematic BMI.

- 3) Planning the intervention

- ✓ upper and lower instrumented vertebra
- ✓ determining the number of instrumented vertebrae in the thoracic and lumbar zone,
- ✓ type of fusion – screws, possible use of laminar and pedicle hooks, as well as sublaminar bands.
- ✓ for rigid curves with kyphosis - planning osteotomies (Ponte).

The distribution of the patients, part of the study, as per Lenke classification is the following– Lenke 1 -2 patients, Lenke 2 -11 patients, Lenke 3 -21 patients, Lenke 4 -4 patients / see Fig.1/.

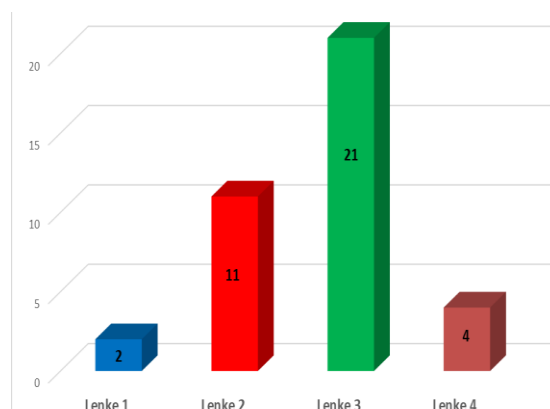


Fig.1

The inclusion criteria for participating in the study were MT (main thoracic) curvatures with a Cobb angle greater than 60 degrees. The preoperative values of the Cobb angle in the studied series were 72-116°. The included cases had rigid MT curvatures with correction below 40% on bending and traction X-rays, and the levels of correction on specialized X-rays were 2-34%. (See Fig.2, Fig.3, Fig.4).

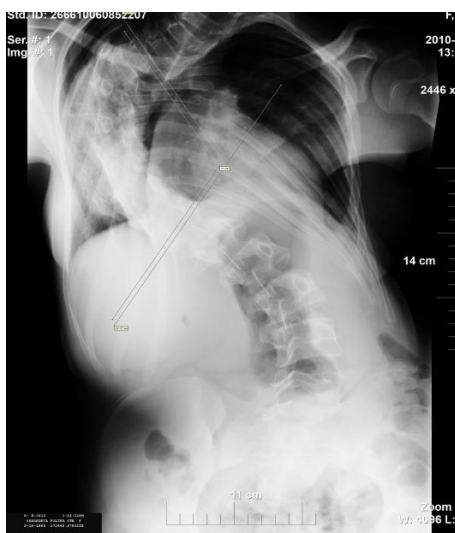

Fig.2. 11yF MT Cobb 112 AP, standing position

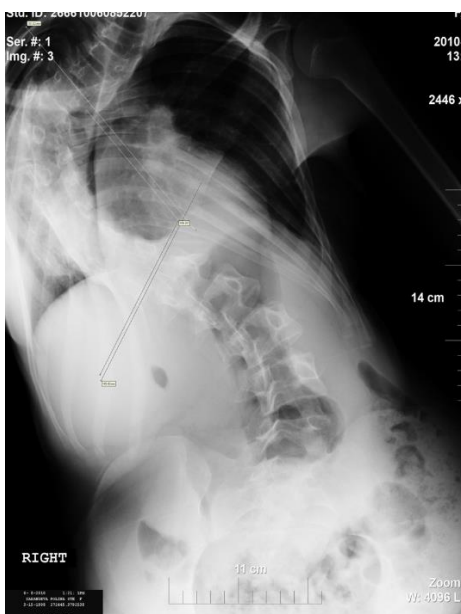

Fig.3 11yF R bending Cobb 109°

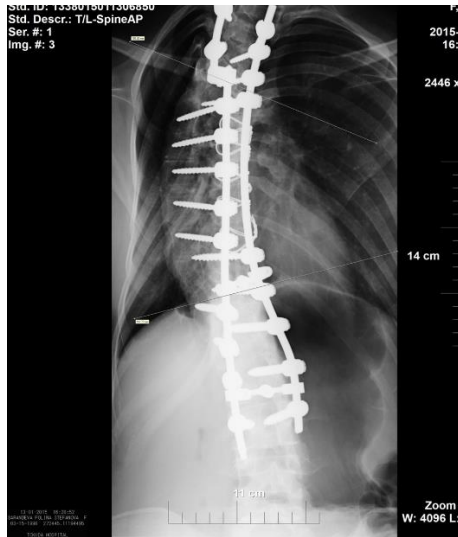

Fig.4. 11yF MT Cobb 40° postop

Kyphosis in the T5-T12 segment was also reported during the preoperative planning. The used technique was posterior stabilization. The pedicle screws were placed by using the free-hand technique respecting the verification protocol in positioning of the pedicle screws. The operative interventions were carried out in the conditions of MIOM. POs were performed after positioning the pedicle screws. The time to perform the osteotomy at one level and the blood loss at osteotomy at one level were reported. The levels of correction of one level of osteotomy in the sagittal plane in cases with pronounced kyphosis and in the coronal plane are reported.

3 Results

Osteotomies were performed at 3 to 5 levels in the following cases. In 26 cases they were at 3 levels, in 7 cases at 4 levels and in 5 cases at 5 levels (See Fig.5).

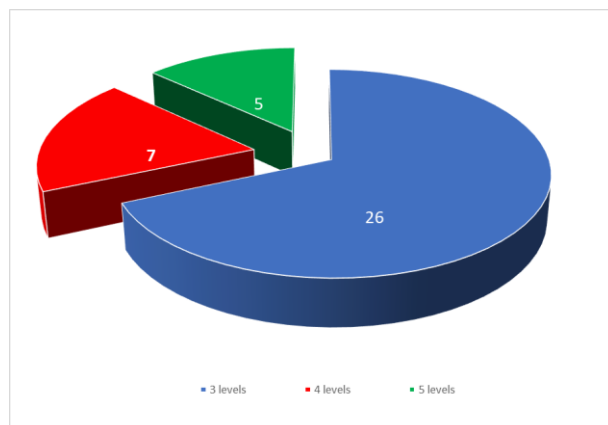


Fig.5 Distribution of number of osteotomies

Frontal and sagittal plane corrections, blood loss per osteotomy level, and blood loss per osteotomy level were reported. The correction of MT curve is 42-74%, the correction of kyphosis in the segment (T5-T12) is 12-42%. The blood loss at one level of osteotomy is 50-95 ml, and the time registered at one level of osteotomy is 19-28 min. (See Fig.6, Fig.7)

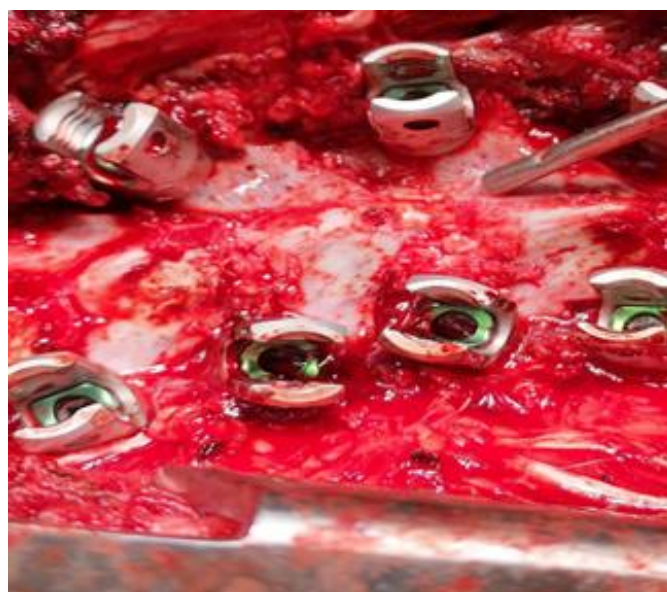

Fig.6 before osteotomy

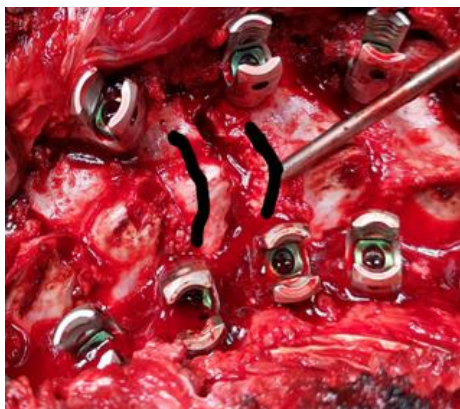

Fig.7 after osteotomy

When examining the levels of correction at one level of osteotomy, 8-11 degrees were found in kyphosis and in the coronal plane - < 5 degrees.

4 Complications

In the monitored series, 7 cases of arterial pressure drops and loss of MIOM potentials were registered during the implementation of PO.

When tracking malpositions of the pedicle screws, an average level of 8.46% was found. The greater number was identified in the lateral malpositions (66.7%), see Fig.8. This result was reported based on the postoperative X-rays. The registered malpositions are reported in the so-called “safe zone” (2 mm deviation from the walls of the pedicle), which is the reason for not performing reoperation for repositioning the screws. There were no MIOM data registered on the intraoperative neurological complications, as well as there were no clinical data on postoperative neurological problems.

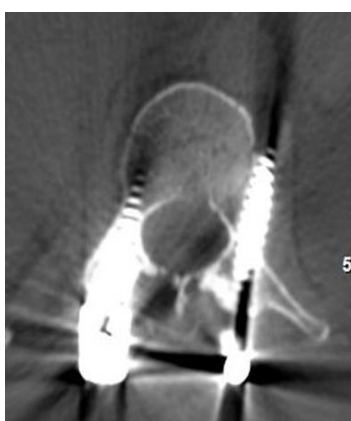


Fig.8. Lateral malposition

5 Discussion

POs were planned and performed in cases of pronounced deformities with reported rigidity of the curves, as well as in cases with pronounced thoracic kyphosis or hypolordosis. Prior to the osteotomies, a mandatory consultation with the anesthesiologists' team took place in relation to the patient's overall physical status and the generated blood loss up to date. In the above-described complications including blood pressure drops and loss of MIOM potential, it was necessary to abort the operative procedure and start measures to restore the levels of the blood pressure and MIOM potentials, in order to allow the continuation of the surgical procedure.

The technical execution of PO is performed in stages. We prefer to perform osteotomies after the placement of the pedicle screws. The reason is that the used free-hand technique requires traceable bone markers, which could be problematic if a PO was previously performed. The osteotomy should be performed at the preoperatively planned levels of the tip of the scoliotic and kyphotic deformity. The osteotomy is performed stepwise, starting with resection of the spinous processes and interspinous ligaments, followed by a partial laminectomy, resection of the ligamentum flavum, then continuing with the partial laminectomy going from the mid-vertebral to the lateral side. The continuation of the partial laminectomy and resection of the processes articularis is usually first on the convex side. On the concave side, the spinal cord is quite intimately close to the bone structures, and the primary resection on the convex side gives greater visibility in this neuralgic area. After the osteotomies are performed, the area is covered with Gelaspon to minimize any bleeding. Covering the osteotomy areas with Gelaspon also prevents the entry of bone fragments from the bone plastic material. After PO a clinical increase in mobility is registered in the zone of rigid deformities. PO also creates conditions for using hybrid syntheses with sublaminar bands. At the beginning of the study period, wires were used more often with step-by-step tension in the process of translation in the deformation zone and achieving the possible reposition.

The use of wires and a possible osteoporosis could present a condition for violation of the vertebral lamina. In subsequent stages, the use of sublaminar bands with a larger bearing surface on the bone structure, have minimized the risks of bone damages. During the surgery, a high density of the synthesis was required for a better control of the deformations during the repositioning. The presence of a big rotation in the apical zones was a challenge in the positioning of screws, especially on the concave side. This feature of the deformity, as well as the cases with hypokyphosis, were one of the reasons for using sublaminar bands and gradual translation to the pre-contoured rod in the course of repositioning.

Ponte osteotomies in large AIS thoracic curves treated with sublaminar bands allow more effective corrective maneuvers that improve coronal correction without significant loss during follow-up¹¹. The sagittal profile appears to be determined by other variables; however, Ponte osteotomies facilitate contouring of the desired kyphosis.

Fei Wang et al.¹², considered that a Ponte osteotomy involving posterior release and lengthening of the posterior column could result in postoperative restoration of normal thoracic kyphosis in patients with hypokyphotic AIS. Rod material, rod diameters, and fusion density play a role in outcomes in the hypokyphosis correction. The use of a 6.0

mm diameter Co–Cr rod and high pedicle fusion density together with PO at the tip of the deformity can optimize the sagittal correction in a hypokyphotic patient. The same authors considered that the Ponte osteotomy could achieve release of the posterior bony structures to increase the flexibility of the deformity, so as to improve the correction of the major coronary curve in patients with AIS. To some extent, implants and surgical technology can also affect coronary correction. There are quite divergent data in the literature regarding the increase in operative time and blood loss with PO. Basically, the surgeon's good operative technique and the number of performed osteotomies have a key role in the discussion of increased operative time and increased blood loss.

6 Conclusion

Ponte osteotomy and instrumentation with pedicle screws is an effective and relatively safe surgical method to achieve good sagittal and frontal correction in cases with pronounced and rigid thoracic deformities. The implementation of osteotomies is associated with increased blood loss and operative time, but it is of key importance for achieving improvement mainly of the sagittal disorder in cases of hyper or hypokyphosis.

References

1. R.A. Hibbs A report of fifty-nine cases of scoliosis treated by the fusion operation J Bone Joint Surg Am (1924)
2. J.H. Moe A critical analysis of methods of fusion for scoliosis: an evaluation in two hundred and sixty-six patients J Bone Joint Surg Am (1958)
3. M.N. Smith-Petersen et al. Osteotomy of the spine for correction of flexion deformity in rheumatoid arthritis J Bone Joint Surg Am(1945)
4. Matthew J Geck 1, Angel Macagno, Alberto Ponte, Harry L Shufflebarger The Ponte procedure: posterior only treatment of Scheuermann's kyphosis using segmental posterior shortening and pedicle screw instrumentation Spinal Disord Tech 2007 Dec;20(8):586-93. doi: 10.1097/BSD.0b013e31803d3b16 PMID: 18046172
5. H.L. Shufflebarger et al.Effect of wide posterior release on correction in adolescent idiopathic scoliosisJ Pediatr Orthop B (1998)
6. Harry L Shufflebarger 1, Matthew J Geck, Cynthia E Clark The posterior approach for lumbar and thoracolumbar adolescent idiopathic scoliosis: posterior shortening and pedicle screws Spine (Phila Pa 1976) 2004 Feb 1;29(3):269-76; discussion 276. doi: 10.1097/01.brs.0000109881.63411.48.PMID: 14752348
7. Ponte , Orlando G, Siccardi GL. The True Ponte Osteotomy: By the One Who Developed It Spine Deform. 2018 Jan;6(1):2-11. doi: 10.1016/j.jspd.2017.06.006.
8. Sangiorgio, S. N., Borkowski, S. L., Bowen, R. E., Scaduto, A. A., Frost, N. L., & Ebramzadeh, E. (2013). Quantification of increase in three-dimensional spine flexibility following sequential Ponte osteotomies in a cadaveric model. *Spine Deformity*, 1(3), 171-178. doi: 10.1016/j.jspd.2013.01.006
9. Shah SA, Dhawale AA, Oda JE, et al. Ponte osteotomies with pediclescrew instrumentation in the treatment of adolescent idiopathic scoliosis. *Spine Deform* 2013;1:196e2

10. Halanski MA, Cassidy JA. Do multilevel Ponte osteotomies in thoracic idiopathic scoliosis surgery improve curve correction and restore thoracic kyphosis? *J Spinal Disord Tech* 2013;26(5):252e5.
11. Javier Pizones 1, Felisa Sánchez-Mariscal, Lorenzo Zúñiga, Enrique Izquierdo Ponte osteotomies to treat major thoracic adolescent idiopathic scoliosis curves allow more effective corrective maneuvers *Eur Spine J* 2015 Jul;24(7):1540-6. doi: 10.1007/s00586-014-3749-1. Epub 2015 Jan 7.
12. Wang, F., Chen, K., Ji, T. et al. Do hypokyphotic adolescent idiopathic scoliosis patients treated with Ponte osteotomy obtain a better clinical efficacy? A preliminary retrospective study. *J Orthop Surg Res* 17, 491 (2022). <https://doi.org/10.1186/s13018-022-03390-0>

Author

Adelin Ivanov, M.D., is a member of the Bulgarian Orthopedic and Traumatology Association (BOTA). He is assistant at the Department of Orthopedics and Traumatology at the Faculty of Medicine, Sofia University, and an orthopedic surgeon at the Department Orthopedics and Traumatology, Acibadem City Clinic Tokuda Hospital, Sofia, Bulgaria.