# Mechanics of Peroneus Longus Subluxation: Current Concepts in Diagnosis and Management

Nirmal Nachiketh Binu[1], Reuel Abraham Kurudamannil[2], Binu Sasidharan[3], Simran Arora[4], Said Obied[3], Sahithya Madhusoodanan Varier[5], Ram Sudhan S[6] (✉)

[1]Ras Al Khaimah Medical and Health Sciences University, Ras Al Khaimah, UAE
[2]Cleveland Clinic Abu Dhabi, Abu Dhabi, UAE
[3]NMC Specialty Hospital, Abu Dhabi, UAE
[4]University of Debrecen, Debrecen, Hungary
[5]Nicolae Testemițanu State University of Medicine and Pharmacy, Chișinău, Moldova
[6]Department of Orthopaedics, P.K. Das Institute of Medical Sciences, Vaniamkulam, Kerala, India

sudhansubramaniam@yahoo.com

DOI: 10.58542/jbota.v63i1.252

**Abstract—** Delayed recognition of Peroneus longus subluxation may result in recurrent tendon instability, chronic pain, tendon degeneration, and impaired functional outcomes. This review provides a comprehensive overview of the current understanding of the biomechanics, pathophysiology, diagnosis, and management of peroneus longus subluxation. Contemporary concepts regarding injury mechanisms, risk factors, and classification systems, including intrasheath instability are discussed. Particular emphasis is placed on advances in diagnostic imaging, highlighting the complementary roles of dynamic ultrasonography, magnetic resonance imaging, computed tomography, and conventional radiography, together with common diagnostic pitfalls. Current treatment strategies, ranging from conservative management to modern surgical techniques, including superior peroneal retinaculum repair, endoscopic stabilization, retinacular augmentation, groove-deepening procedures, ligament rerouting, and bony reconstructive techniques, are evaluated with respect to their indications, technical principles, and reported clinical outcomes. Although surgical intervention consistently demonstrates excellent functional recovery and low recurrence rates in symptomatic or recurrent cases, important controversies remain regarding the management of isolated peroneus longus instability, the clinical significance of retromalleolar groove morphology, and the comparative long-term outcomes of available procedures. This review synthesizes the contemporary evidence to facilitate accurate diagnosis, guide individualized treatment, and identify priorities for future research in this uncommon but challenging disorder.

**Keywords—** Peroneus longus; Tendon subluxation; Intrasheath instability; Superior peroneal retinaculum; Dynamic ultrasonography; Surgical stabilisation.

## 1. Introduction

Peroneus longus dislocation or subluxation is a rare ankle injury, comprising 0.3-0.5% of all traumatic cases, often misdiagnosed as lateral ankle sprain[1], with a reported prevalence of approximately 21–39% in association with talar fractures[2]. It arises from forceful dorsiflexion-eversion with peroneal contraction, disrupting the superior peroneal retinaculum (SPR) and allowing anterior tendon displacement over the fibula[3]. Multiple factors have been proposed as contributors, including anatomical morphology and variations, physical activity levels, and concomitant ligamentous laxity[4]. If left untreated, this condition may progress to chronic instability and subsequent tendon degeneration or tears[5]. Advances in imaging modalities, particularly dynamic ultrasonography and high-resolution MRI, have enhanced diagnostic accuracy and facilitated real-time assessment of tendon instability[3].

Despite advances in ankle imaging and surgical techniques, peroneal tendon dislocation or subluxation remains frequently missed or misdiagnosed, leading to recurrent subluxation episodes, progressive tendon degeneration, instability and delayed intervention[6] compromising long-term ankle function and patient outcomes[5]. The lack of standardized management protocols further exacerbates suboptimal recovery rates in both acute and chronic presentations[7]. Surgical solutions, including SPR repair, fibular groove deepening, bone block augmentation, or retinaculum reconstruction, stabilize the tendons and yield high success rates (80-95% satisfaction)[8]. Recent studies confirm excellent functional outcomes, with AOFAS scores averaging 92.9 and rapid return to sport, particularly combining SPR repair with groove deepening[9]. Endoscopic and open techniques show comparable efficacy, minimizing complications[9].

Regardless of the advances in understanding peroneal tendon pathology and surgical strategies, significant gaps persist. First, most series pool longus and brevis pathology, making it difficult to delineate the distinct biomechanics, injury patterns, and prognostic factors for isolated longus instability[10]. Second, the contribution of retromalleolar groove morphology remains controversial, with some MRI-based studies finding no significant difference between patients with recurrent dislocation and controls, while others emphasize flat or convex grooves as key risk factors[3]. Third, Dynamic intrasheath subluxation of the peroneus longus tendon, occurring either over an intact peroneus brevis tendon or through a split tear of the peroneus brevis, has been described predominantly in imaging-based studies. However, its natural history, optimal surgical indications, and comparative clinical outcomes remain inadequately defined[10]. Finally, high-quality prospective data on long-term recurrence, reoperation, and functional recovery after different stabilization strategies in athletes versus non-athletes are lacking[5].

These persistent diagnostic and therapeutic challenges highlight a critical gap in current orthopaedic practice, where peroneal tendon pathologies continue to evade timely recognition despite technological progress[3]. Thus, we aim to present a comprehensive narrative synthesis of the existing literature on peroneus longus subluxation, critically appraising its epidemiology, underlying pathophysiology, diagnostic modalities, therapeutic strategies, and clinical outcomes to support evidence-based practice and delineate areas requiring further research.

## 2. Relevant Anatomy

The peroneus longus (PL) muscle arises from the lateral fibular head and proximal two-thirds of the fibular shaft, inserting distally at the base of the first metatarsal and medial cuneiform[10], with an elongated myotendinous junction giving rise to the distal tendon well above the ankle. Its course is long and complex, making two sharp turns at the retromalleolar region and cuboid tunnel before insertion[10]. At the ankle, the tendon lies in the retro-malleolar groove lying posterior to the peroneus brevis tendon, with both tendons enclosed within the common peroneal synovial sheath (Figure 1) which spans from 4 cm proximal to 1 cm distal to the lateral malleolus well secured by the superior peroneal retinaculum (SPR)[11]. The SPR arises from the posterolateral fibular margin and inserts posteriorly onto the calcaneus and Achilles tendon (Figure 1)[12], with its incompetency representing the primary and most common cause of peroneal tendon instability. The acute turns of the peroneus longus tendon are the most common sites for injuries, likely due to high tensile and shear stresses, notably, the retromalleolar groove constitutes the principal locus of instability, wherein subluxation or dislocation occurs anteriorly from the groove and affects the longus more commonly than the brevis, due to various reasons discussed later in this article[10].

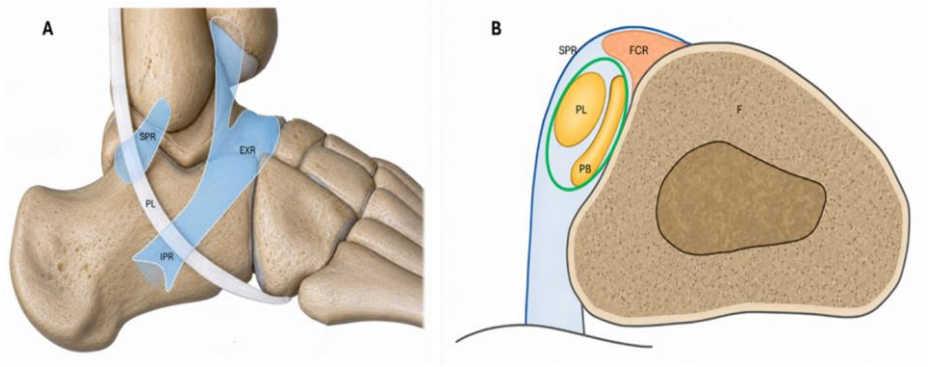


**Figure 1.** (A) Schematic representation of the lateral aspect of the ankle depicting the course of the peroneus longus tendon and the principal anatomical structures that maintain tendon stability. (B) Axial schematic illustration of the distal fibula at the level of the retromalleolar groove demonstrating the osseous and soft-tissue components of the groove and the peroneal tendons contained within it. *(PB- peroneus brevis; PL - peroneus longus; SPR-superior peroneal retinaculum; FCR-fibrocartilaginous ridge; F-fibula.)*

### 2.1 The Retromalleolar Groove

The posterior surface of the lateral malleolus is limited laterally by an oblique crest and medially by the extension of the posterior border of the fibular shaft, this surface is hallowed by a depression, the retromalleolar groove (Figure 2). The retromalleolar groove is typically oriented posteriorly at an angle of 64°–78°, with a mean width of 6–9 mm and depth of 2–3 mm, and is predominantly concave in morphology (82%), while flat and convex variants occur in 11% and 7% of individuals, respectively; notably,

approximately 10% of cases lack a discernible peroneal tendon imprint (Figure 2C&D)[13]. The retromalleolar groove constitutes a fibro-osseous tunnel formed by the osseous floor of fibula and its variable periosteal structure, which transitions proximally from thin, purely fibrous tissue overlying the sulcus of the bone to a thick distal fibrocartilaginous cushion that imparts concavity where the underlying cortex is intrinsically convex[14]. The lateral margin of the groove extends into a prominent ridge, most pronounced 3–10 mm proximal from the malleolar tip to which the superior peroneal retinaculum attaches, rendering the deepest segment in the groove. The periosteal cushion on the medial aspect of the groove comprises the posterior talofibular ligament distally and the posterior inferior tibiofibular ligament proximally, both exhibiting fibrocartilaginous entheses conferring a predominant fibrocartilaginous rim to the groove's medial border relative to the lateral side (Figure 1B)[14]. The superior peroneal retinaculum (SPR) transforms the retromalleolar groove into a fibro-osseous tunnel, which is lined proximally by the parietal synovial sheath but lacks this reinforcement distally, resulting in a relatively weak restraint to the peroneal tendons[15].

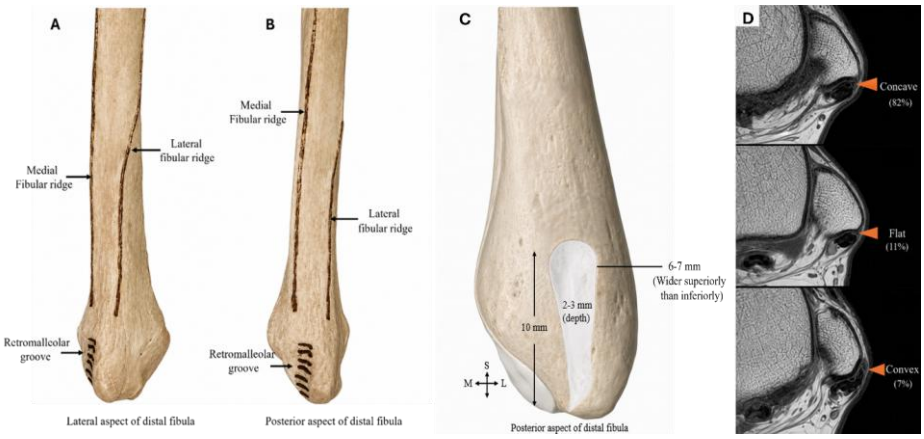


**Figure 2. Anatomy, morphometry, and morphological variations of the retromalleolar groove.** (A) Cadaveric image of the lateral aspect (A) and posterior aspect (B) of the distal fibula demonstrating the anatomical landmarks and markings of the retromalleolar groove. (C) Schematic illustration of the posterior aspect of the distal fibula depicting the morphometric dimensions of the retromalleolar groove and its cartilaginous lining. (D) Magnetic resonance (MR) images of the distal fibula demonstrating the various morphological patterns of the retromalleolar groove that may predispose to peroneal tendon subluxation, along with their reported incidence in the general population

### 2.2 Peroneus Quartus Muscle

The peroneus quartus is an accessory muscle seen in 7– 22% of population. It commonly arises from the peroneus brevis muscle and has a variable insertion, typically onto the retrotrochlear eminence of the calcaneus. This muscle aids in foot pronation, and can be seen on MRI and ultrasound lying posteromedial to the peroneus longus and brevis[16].

## 3. Biomechanics

Peroneal tendon subluxation or dislocation represents a dynamic instability of the peroneal tendons at the level of the lateral malleolus, during physiological loading[17]. The peroneal muscles function as the primary evertors of the foot and dynamic stabilizers against inversion stress, particularly during gait and athletic activities that require rapid directional changes[18]. Biomechanically, the peroneus longus forms a distinctive twopulley system along its anatomical course, with the retromalleolar groove at the lateral malleolus and the cuboid tunnel functioning as fixed pulleys with the variable tendon segments on either side (Figure 3) constituting the lever arms that guides the tendon in two different acute directional changes amplifying the tensile forces transmitted through the tendon during dynamic foot movements[10]thereby imposing substantial mechanical stress upon both the tendon and its restraining structures[19] rendering them susceptible to failure, particularly when associated with underlying anatomical variants or physiological risk factors[19].

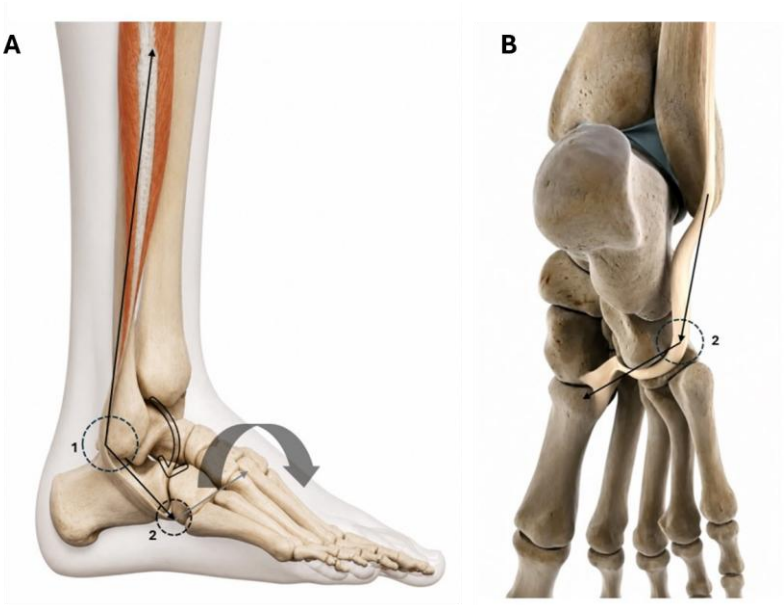


**Figure 3. Biomechanics of the peroneus longus tendon.** (A) Schematic illustration of the lateral aspect of the ankle and (B) the plantar aspect of the foot demonstrating the biomechanical course of the peroneus longus tendon. The tendon traverses a functional two-pulley system, with the retromalleolar groove constituting the first pulley and the cuboid tunnel the second (dotted circles). These fixed pulleys redirect the tendon through two sequential acute changes in direction, while the intervening tendon segments function as lever arms (black arrows) to optimize force transmission and enhance eversion both in dorsiflexion and in plantarflexion.

When there is excessive eccentric loading, the dynamic muscular forces exceed the restraining capacity of static stabilizers (the superior peroneal retinaculum (SPR) and

the fibular groove) ultimately resulting in the failure of the fibro-osseous containment mechanism. The superior peroneal retinaculum (SPR) exhibits variable morphology, featuring a proximal double-layered structure (along with the parietal layer) and a distal single-layered (absence of parietal layer) configuration predisposing to failure at the distal segment, permitting anterior displacement[12] which consequently progresses to complete tear on continuing physical activity.

### 3.1 Pathophysiology

Chronic mechanical irritation and relatively limited vascular supply to portions of the tendon may further predispose the tissue to degenerative changes and tendon tears[20]. Chronic instability may also promote osseous remodeling of the lateral fibular cortex (osteophytes) and predispose to secondary tendon pathology, including longitudinal split tears of the peroneus brevis, which occur due to repetitive compression of the tendon within the retromalleolar groove[21].

## 4. Mechanisms of Injury

Mechanically, dislocation or subluxation most commonly results from forceful peroneal contraction during sudden dorsiflexion with inversion or eversion classically occurs in skiing, cutting sports, and high-energy ankle trauma[1]. In this setting, the SPR may get individually detached from the fibrocartilage (FCR) and the periosteum yet may remain continuous, or it may get avulsed along with the FCR and the periosteum or with a fleck of bone else the SPR may itself get ruptured[22] owing to a series of injury patterns classified as Eckert and Oden types discussed later. Intra-sheath instability might also occur, where the longus subluxates over or through the brevis while the SPR remains intact, reflects altered tendon-tendon mechanics within a crowded or stenotic sheath rather than frank retinacular failure[23].

Fracture-associated mechanisms are increasingly recognized. Up to one-third of operatively treated talar fractures and a similar proportion of displaced intra-articular calcaneal fractures show peroneal tendon displacement, often with an associated "fleck sign" at the fibular or calcaneal retinacular insertion[2]. In these injuries, lateral wall blow-out, retrotrochlear eminence involvement, and comminution can either entrap or displace the peroneus longus, compounding instability and complicating reduction[2].

## 5. Clinical Symptoms and Examination

Clinically, patients typically report lateral or posterolateral ankle pain, swelling, and a subjective sense of "snapping" or "popping" behind or over the fibula, often exacerbated by cutting, pivoting, or walking on uneven ground[24]. Many describe recurrent episodes of giving way or instability, and in chronic cases there may be visible prominence of the tendons anterior to the malleolus or a palpable ridge over the distal fibula[25].

Examinations should document hindfoot alignment, arch height, and evidence of cavovarus or associated ligamentous laxity. Palpation along the peroneal course may reveal focal tenderness at the retromalleolar groove, peroneal tubercle, or cuboid tunnel,

and resisted ankle eversion and first-ray plantarflexion can reproduce pain or weakness, particularly with peroneus longus involvement[26]. The peroneal compression test, pain elicited by dorsiflexion-eversion with manual pressure over the fibular groove has been proposed to indicate brevis pathology but often coexists with longus disease[27].

Dynamic provocative tests are central to diagnosing instability[17]. With the patient prone or seated, active dorsiflexion-eversion or circumduction against resistance may demonstrate peroneal snapping or frank displacement over the lateral malleolus[28]. Intrasheath subluxation can be subtler, manifesting as tendon "switching" without overt anterior displacement and may not be appreciable without dynamic imaging[29]. Chronic cases can show localized atrophy, weakness of eversion, and signs of concomitant painful os peroneum or midfoot tenderness related to distal longus pathology[21].

## 6. Classification

Eckert et al.[30] classified peroneal tendon dislocations into three types (Figure 4) based on the pattern of injury to the fibrocartilaginous ridge and the superior peroneal retinaculum, and Oden et al. subsequently added a fourth type,

- Type I: Dislocation occurs when the superior peroneal retinaculum is detached together with the fibrocartilaginous ridge and the periosteum from the anterior aspect of the fibula. This is the most commonly reported type, accounting for 51% of cases.
- Type II: Dislocation occurs with avulsion of the fibrocartilaginous ridge, superior peroneal retinaculum, and periosteum from the anterior surface of the fibula as a single unit. This type accounts for 33% of cases.
- Type III: This type is characterized by an avulsion fracture of the anterior fibular cortex involving the fibrocartilaginous ridge and superior peroneal retinaculum, with an incidence of 13%.
- Type IV: This rare type, later described by Oden et al., involves isolated rupture of the superior peroneal retinaculum (Figure 4D); its exact frequency remains unknown[31].

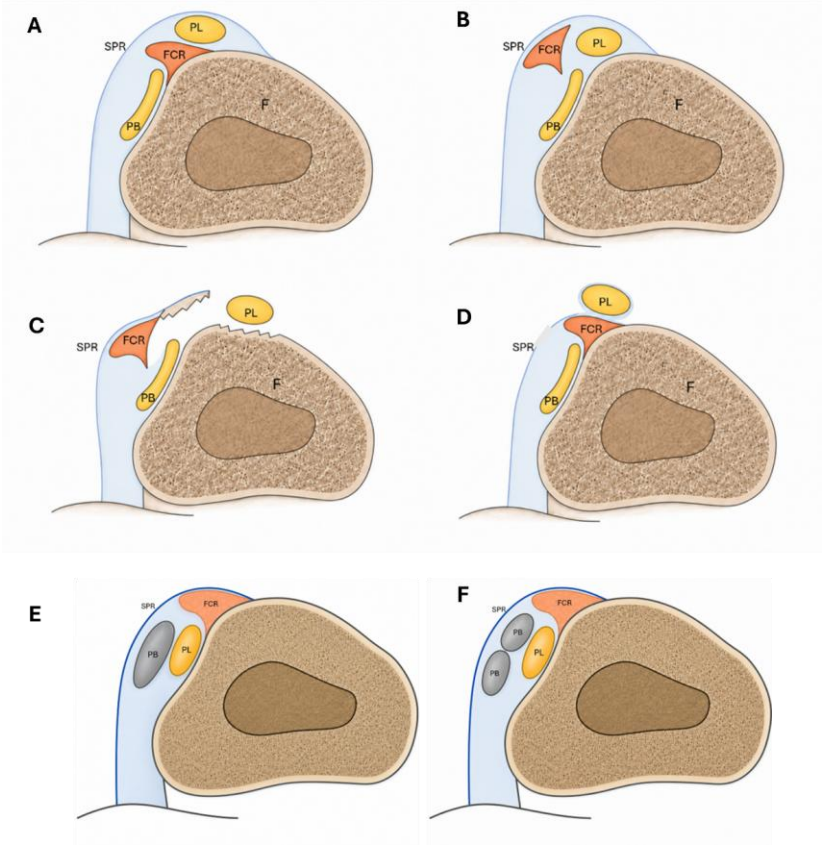


**Figure 4. Classification of peroneal tendon instability.** (A–D) **(A) Type I:** Elevation of the superior peroneal retinaculum (SPR) from the fibrocartilaginous ridge (FCR) and fibula, with the FCR remaining attached to the retinaculum and periosteum while the SPR attachment remains intact. **(B) Type II:** Avulsion of the SPR together with the FCR and anterior fibular periosteum, resulting in anterior displacement of the peroneal tendons. **(C) Type III:** Avulsion fracture of the anterior fibular cortex (fleck sign) with the SPR and FCR attached to the avulsed bony fragment. **(D) Type IV:** Complete rupture of the SPR without periosteal or bony avulsion, allowing peroneal tendon dislocation. (E–F) Raikin's classification of intrasheath peroneal tendon subluxation showing **Type A**, positional interchange between the tendons with an intact SPR and **Type B**, subluxation of the peroneus longus (PL) through a longitudinal split tear of the peroneus brevis (PB). *(SPR, superior peroneal retinaculum; FCR, fibrocartilaginous ridge; PL, peroneus longus; PB, peroneus brevis; F, fibula*)

### 6.1 Intrasheath Subluxation

Intrasheath subluxation of the peroneal tendons represents a distinct form of peroneal tendon instability in which the peroneus longus and peroneus brevis tendons interchange their relative positions within the retromalleolar groove while the superior peroneal retinaculum remains intact (Figure 4E-F). This entity is clinically important be-

cause patients may present with retrofibular pain, snapping, or clicking despite the absence of demonstrable frank dislocation on physical examination, making diagnosis dependent on a high index of suspicion and dynamic imaging[32]. Raikin et al. identified intrasheath subluxation in 14 of 57 patients with painful peroneal snapping in the retromalleolar groove and described two subtypes: type A, in which the tendons are structurally intact and merely switch positions, and type B, in which the longus tendon subluxates through a longitudinal split tear of the brevis tendon[32].

## 7. Diagnostic Methods

Plain radiographs are recommended in all suspected cases to exclude fractures and assess hindfoot alignment; a small cortical avulsion ("fleck sign", Figure 5A) at the fibular or calcaneal retinacular insertion strongly suggests SPR injury and peroneal dislocation in both talar and calcaneal fractures[33]. Weight-bearing views and Harris heel projections help evaluate cavovarus deformity and peroneal tubercle hypertrophy[34].

Ultrasound provides high-resolution assessment of tendon morphology, tenosynovitis, and dynamic instability[17]. It can demonstrate thickening, hypoechogenicity, split tears, sheath fluid, and dynamic evaluation with resisted dorsiflexion-eversion (Figure 5B) and has shown near-perfect sensitivity and specificity for extra-sheath subluxation and intrasheath instability compared with operative findings[35]. Ultrasound is particularly valuable for visualizing transient displacement that may not be captured on static MRI[36].

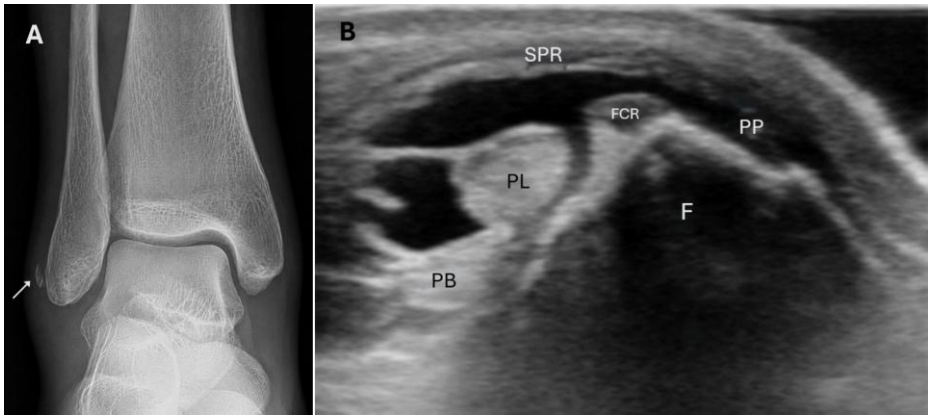


**Figure 5. Radiographic and ultrasonographic findings in peroneal tendon dislocation.** (A) Anteroposterior radiograph of the right ankle demonstrating the fleck sign (white arrow), indicative of avulsion of the superior peroneal retinaculum. (B) Ultrasonographic image following injection of fluid into the peroneal tendon sheath. The appearance of a positive pooling sign (PP) confirms the presence of pseudo pouch by demonstrating extravasation of fluid through the separation of the SPR confirming the diagnosis of peroneal tendon dislocation

Computed tomography (CT) is most useful in the fracture setting, delineating retromalleolar groove morphology, fibular fleck avulsions, peroneal tubercle size, and tendon entrapment by displaced fragments[37]. Three-dimensional reconstructions and color volume-rendered CT have been shown to improve detection of peroneal displacement in calcaneal fractures, and CT-based measurements are used to quantify neo-groove depth after deepening procedures[38].

Magnetic resonance imaging (MRI) offers comprehensive evaluation of the entire peroneus longus, associated peroneal and ligamentous pathology, and bony morphology. High-resolution protocols can accurately detect tendinosis, partial and complete tears, stenosing tenosynovitis, os peroneum lesions, and magic-angle (effect) artifacts must be recognized to avoid false positive tendinopathy[39]. Recent data indicate 100% sensitivity and specificity of MRI for peroneus longus tears in surgically correlated series, although earlier reports showed more modest accuracy[40]. MRI is less sensitive than dynamic ultrasound for intrasheath subluxation because tendons may appear normally located at rest[35].

## 8. Pitfalls in Assessment

Accurate diagnosis of peroneus longus tendon instability remains challenging because clinical symptoms are often nonspecific and imaging findings may be subtle or transient. Although radiography, ultrasonography (US), and magnetic resonance imaging (MRI) play complementary roles in evaluation, each modality has inherent limitations and potential pitfalls[39].

### 8.1 Pitfalls of Ultrasonography

Dynamic ultrasonography is considered the imaging modality of choice for detecting peroneal tendon instability because tendon subluxation and dislocation are predominantly dynamic phenomena that may not be apparent on static imaging[29]. However, several pitfalls may lead to misdiagnosis. First, inadequate dynamic assessment during forced dorsiflexion and eversion may fail to reproduce tendon instability, resulting in false-negative examinations. Second, operator dependency and variability in examination technique can affect diagnostic accuracy. Third, transient intrasheath tendon switching may occasionally be observed in asymptomatic individuals, making it difficult to distinguish physiological tendon motion from pathological instability[29]. In addition, anisotropy artifacts, which are common during tendon imaging, may mimic tendinopathy or partial-thickness tears if the ultrasound beam is not maintained perpendicular to the tendon fibers. Furthermore, anatomical variants such as a low-lying peroneus brevis muscle belly, accessory peroneus quartus muscle, or altered retromalleolar groove morphology may be difficult to characterize completely with ultrasonography alone and may require correlation with MRI[41]. Dynamic ultrasound is therefore highly sensitive for instability but should be interpreted in conjunction with clinical findings and knowledge of normal anatomical variations[17].

### 8.2 Pitfalls of Magnetic Resonance Imaging

MRI provides excellent visualization of tendon morphology, retinacular injuries, bone marrow abnormalities, and associated anatomical variants. Nevertheless, MRI is fundamentally a static imaging modality and may fail to demonstrate dynamic tendon subluxation or dislocation occurring only during provocative maneuvers[39]. Consequently, normal MRI findings do not exclude clinically significant peroneal tendon instability. Another important pitfall is the magic-angle phenomenon, which may produce increased intratendinous signal intensity on short echo-time sequences and mimic tendinosis or partial tendon tears. Recognition of this artifact is essential to avoid overdiagnosis[42]. Additional diagnostic challenges include distinguishing true longitudinal split tears from normal tendon flattening, bifid morphology, or pseudolesions related to tendon orientation. Variants such as a bifurcated or crescentic peroneus brevis tendon, insertion of a peroneus quartus tendon, and os peroneum may also be mistaken for pathological abnormalities[43]. Furthermore, MRI assessment of the superior peroneal retinaculum (SPR) may be limited in chronic injuries where retinacular attenuation or scarring is subtle[44].

### 8.3 Pitfalls of Radiography

Conventional radiography has a limited role in the direct assessment of peroneal tendon instability because soft-tissue structures, including the tendons and SPR, are poorly visualized. Standard radiographs may therefore appear normal despite significant tendon instability[17]. Although radiographs can identify indirect signs such as avulsion fractures of the distal fibula (fleck sign), os peroneum abnormalities, retromalleolar groove morphology, or associated fractures, they are insensitive for detecting tendon subluxation itself. Subtle anatomical risk factors, including shallow retromalleolar grooves or accessory musculotendinous structures, are often not adequately characterized on plain radiographs. As a result, radiographic findings should be interpreted as adjunctive rather than definitive in the evaluation of peroneal tendon disorders[17].

## 9. Risk Factors

A shallow, flat, or convex retromalleolar groove and absent or attenuated fibrocartilaginous ridge can reduce bony containment of the tendon, although recent MRI-based work suggests that fibular morphology alone may not differ significantly between patients with and without dislocation[45]. Low-lying peroneus brevis muscle belly and presence of a peroneus quartus muscle increase intra-sheath volume, "overstuff" the tunnel, and stretch the SPR, predisposing to longitudinal splitting, tenosynovitis, and instability[46]. Cavovarus and hindfoot varus alignment shift load laterally, increasing friction and compressive forces on the peroneus longus at the retromalleolar groove, peroneal tubercle, and cuboid tunnel[47].

Hypertrophied peroneal tubercle and retrotrochlear eminence can mechanically impinge the tendon, causing tendinosis, stenosing tenosynovitis, and, in extreme cases, distal dislocation over the calcaneal tubercle[48]. Os peroneum pathology (fracture, diastasis, entrapment) and fibrocartilaginous nodules within the tendon at the calcaneocuboid region alter local biomechanics and are often associated with high-grade peroneus

longus tears and painful os peroneum syndrome[49]. Neuromuscular conditions (e.g., poliomyelitis), generalized ligamentous laxity, and collagen disorders may secondarily lead to peroneal instability through altered muscle control or retinacular insufficiency[50].

## 10. Management

### 10.1 Conservative Management

Conservative treatment is generally reserved for acute peroneal tendon subluxation or dislocation, particularly in compliant patients without major osseous abnormality or recurrent instability. The usual regimen consists of closed reduction when necessary, immobilization in a below-knee cast for four to six weeks, and subsequent protected rehabilitation; taping or strapping alone is associated with poorer control of instability and inferior return-to-activity outcomes. A systematic review found that recurrence rates were substantially lower with cast immobilization for six weeks or more than with taping, with redislocation reported in 17% after prolonged casting compared with 60% after taping. Overall, non-operative treatment prevented recurrent dislocation in approximately 62% to 83% of cases across the available studies, although the evidence base was limited and largely composed of small observational series.

Despite these results, conservative care carries important limitations. Failure is more likely in athletes, delayed presentations, cases with superior peroneal retinaculum avulsion, shallow retromalleolar groove morphology, or associated tendon tears, and persistent pain, snapping, or functional instability often necessitate surgery. Reported complications of non-operative management include recurrent dislocation, chronic lateral ankle pain, activity restriction, and delayed definitive treatment. Intrasheath subluxations are often asymptomatic and requires no specific treatment. However, surgery is indicated if the patient becomes symptomatic and resists conservative treatment.

### 10.2 Surgical Management

#### 10.2.1 Repair of the Superior Peroneal Retinaculum (Modified Das De Procedure)

This technique is commonly indicated in both acute and chronic peroneal tendon dislocations when the retinacular tissue is sufficiently preserved for repair. The surgical technique involved a longitudinal incision extending from the tip of the fibula to approximately 3–4 cm proximally along the posterior aspect of the lateral malleolus to expose the superior peroneal retinaculum (SPR), while the sural nerve is carefully protected. The SPR can be seen forming a false pouch lateral to the lateral malleolus accommodating the subluxed tendons. This false pouch was then incised along its anterior attachment at the lateral malleolus to adequately mobilize the tissue and prepare for anatomical reconstruction[51]. To facilitate stable fixation, four drill holes were carefully created along the lateral ridge of the lateral malleolus securing the tendon their anatomical location within the retromalleolar groove. Subsequently, the SPR was advanced and repaired by suturing it to the dorsal aspect of the lateral malleolus using nonabsorbable sutures (Figure 6) passed through the drill holes[52]. The technique is reported to

successfully provide tendon containment, preserving native bony anatomy, and maintain physiological ankle biomechanics[52]. SH Park et al. in their study of Superior Peroneal Retinaculum (SPR) repair in 36 patients at a mean follow up of 35.6 months reported complete recovery in 34 patients with no everter weakness and full range of motion at the ankle[53].

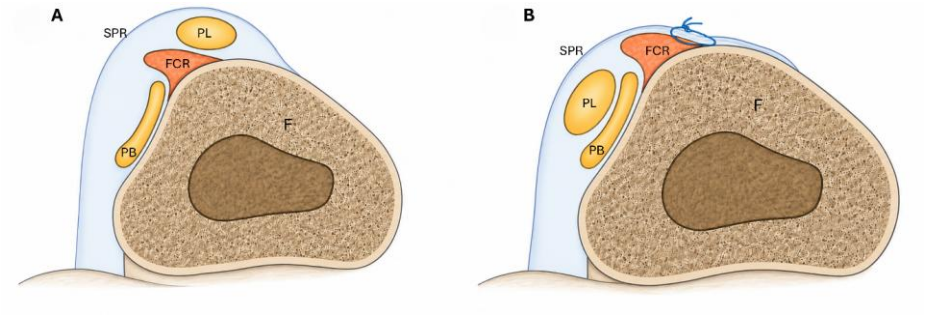


**Figure 6.** Direct SPR repair for peroneal tendon instability. (A) Disrupted superior peroneal retinaculum (SPR) with a false pouch accommodating the subluxated peroneal tendons. (B) Advancement and transosseous repair of the SPR to the lateral malleolus, restoring anatomical containment of the peroneal tendons within the retromalleolar groove

### 10.2.2 Endoscopic Repair of the Superior Peroneal Retinaculum

In recent days endoscopic repair of the SPR become popular and preferred as it warrants early recovery minimising soft tissue related complications. The patient is positioned laterally with a thigh tourniquet. Using a 2.7-mm 30° arthroscope and gravity inflow, proximal and distal portals are established along the peroneal tendon sheath.

Initial tendoscopy evaluates tendon pathology, and any synovitis, low-lying muscle, or tendon tears are addressed as required. The elevated SPR with stripped fibular periosteum is identified, and soft tissue over the lateral cortex of the lateral malleolus is carefully debrided without causing additional periosteal stripping. The exposed lateral cortex is subsequently decorticated to prepare a healing surface. In cases of tendon subluxation or dislocation, the peroneal tendons are reduced and temporarily stabilized within the retrofibular groove using a 1.6-mm K-wire (percutaneously) to improve visualization and to facilitate repair. Two suture anchors (1.8mm) are inserted at the proximal and distal margins of the detached retinaculum. Sutures are passed through the SPR, avoiding tendon capture, and tied while the retinaculum is reduced against the lateral malleolus. Final tendoscopic assessment confirms tendon reduction and repair stability. The procedure can be performed using single-row or double-row suture-bridge techniques. The double-row method may improve tendon-to-bone contact and healing, but it is often reported to cause knot irritation, thus knotless sutures are recommended to reduce this issue. Postoperatively, immobilization in a short-leg cast for three weeks is followed by gradual rehabilitation while avoiding circumduction for three months[54]. Despite being technically demanding, these methods offer cosmetic benefits and may allow earlier return to sport[55].

### 10.2.3 Superior Peroneal Retinaculum Augmentation

Tissue transfer or retinacular reinforcement procedures are typically considered in cases of chronic peroneal tendon instability where the native superior peroneal retinaculum (SPR) is severely attenuated, deficient, or irreparable[56]. SPR augmentation using various adjacent grafts using Achilles tendon, plantaris or Peroneus Brevis or reinforcements using Inferior extensor retinaculum have been reported, the most common procedures are briefed here under.

*Ellis Jones technique*

With patient in lateral position and tourniquet fastened, an approximately 8 cm curvilinear incision was made along the posterior border of the fibula, extending distally around the tip of the lateral malleolus. the SPR, peroneus tendons and the fibular groove were carefully inspected and addressed appropriately. In case the SPR has complex tears that is irreparable with intraoperative provocative testing (ankle dorsiflexion and inversion) reproducing peroneal tendon subluxation, the Achilles tendon is exposed by dissecting posteriorly. Care is taken to preserve the sural nerve and the short saphenous vein. A lateral one-quarter strip of the Achilles tendon, approximately 8 cm long and 5 mm in diameter, was harvested while maintaining its distal insertion on the calcaneus. A transosseous tunnel matching the graft diameter was drilled in an anteroposterior direction through the distal fibula, approximately 2.5 cm proximal to the tip of the lateral malleolus, with the posterior exit placed close to the lateral edge of fibula to prevent tendon displacement. The free end of the tendon graft was passed through the tunnel, turned and sutured back with itself (Figure 7A), reinforcing the periosteum using 1-0 vicryl, with the foot held in dorsiflexion and supination to avoid postoperative restriction of ankle dorsiflexion.[57].

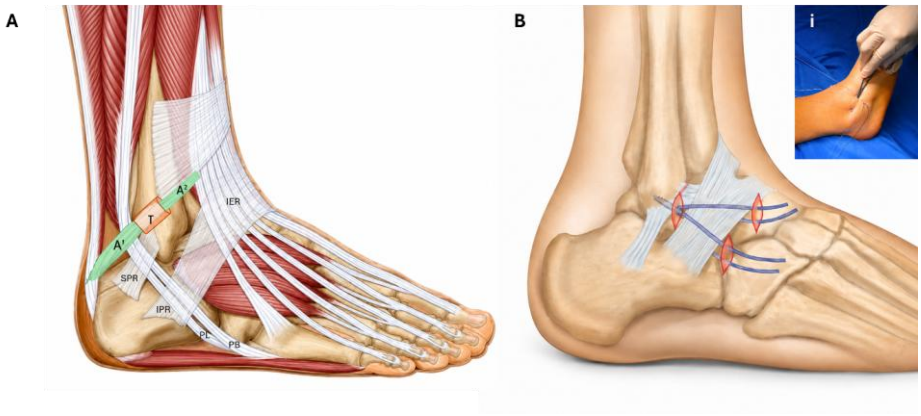


**Figure 7.** Illustrated image of the lateral aspect of ankle demonstrating the Ellis jones technique of Achilleus tendon augmentation (A) with the augmented achilles tendon shown in green. After passing through the tunnel T, the tendon $A^2$ is sutured back to $A^1$. (B) The schematic illustration of IER augmentation (PIERA) via two distal portals (inset: clinical demonstration of the shuttling of sutures above and below the IER through the distal portals)

*Percutaneous Inferior Extensor Retinaculum Augmentation (PIERA)*

Under arthroscopic guidance, a suture anchor was predrilled and inserted at the midpoint between the anterior talofibular ligament (ATFL) and calcaneofibular ligament (CFL) footprints, approximately 1 cm proximal to the distal tip of the fibula, and all four suture strands were retrieved through the anterolateral portal (Figure 7B). Subsequently, two additional 5-mm accessory portals, designated as distal upper and distal lower portals, were established at the distal border of the inferior extensor retinaculum (IER) within the safe zone. These accessory portals also facilitated improved visualization and access to the distal IER when required. A hemostat was introduced through the accessory portals and used sequentially to shuttle the suture limbs along specific tissue planes. One suture limb was passed beneath the subcutaneous tissue and above the IER, while another was passed beneath the IER and retrieved through the corresponding portal (Figure 7B). The remaining two suture limbs were similarly shuttled above and below the IER to complete retinacular capture and reinforcement. With the foot maintained in a neutral position, sutures positioned above and beneath the IER were tied using surgeon's or arthroscopic slip knots followed by square knots for secure fixation. Final hindfoot stability was evaluated using manual anterior drawer and talar tilt tests[58] and closed in layers. Shengxuan Cao et al in their small retrospective series of seven chronic ankle instability patients with attenuated ligament tissue, percutaneous inferior extensor retinaculum augmentation (PIERA) yielded significant improvement in AOFAS (66.9 to 93.7) and CAIT (13.1 to 26.3) scores at mean 16.7month followup, with no major wound, neurologic or instability complications and universal return to recreational sports activity within 6 months.[58]

**10.2.4 Rerouting of the Calcaneofibular Ligament (Platzgummer's Method)**

Rerouting procedures using the calcaneofibular ligament (CFL) represent a soft-tissue surgical technique indicated for recurrent subluxations/dislocations that has failed appropriate nonoperative care, particularly when there is an insufficient superior peroneal retinaculum or when anatomic constraints (shallow fibular groove, marginal fibular fracture, or lax/attenuated retinacular tissue) make primary retinacular repair alone unreliable[59]. A curvilinear incision of appropriate length was made posterior to the lateral malleolus overlying the peroneal tendons. The peroneal tendon sheath was then incised at the level of the fibular tip to expose the underlying structures. The CFL was identified and sharply detached from its fibular insertion at the distal fibular tip. The ligament was subsequently rerouted from its original position deep to the peroneal tendons to a new position superficial to the tendons (Figure 8A& B), thereby ensuring containment of the tendons. The rerouted CFL was then reattached to the distal fibular periosteum using non-absorbable sutures, the remaining SPR is imbricated along with the rerouted CFL. Intraoperatively, the ankle was taken through a full range of motion to evaluate for persistent tendon subluxation. In cases of residual instability, additional plication and tightening of the ligament can be performed[60]. After CFL rerouting, Boykin et al. reported that all seven patients returned to sports within 12 weeks. At a mean follow-up of 20.9 months, there were no recurrences, although postoperative complications were noted in two patients, including one infection and one case of fibrosis that required revision surgery[60].

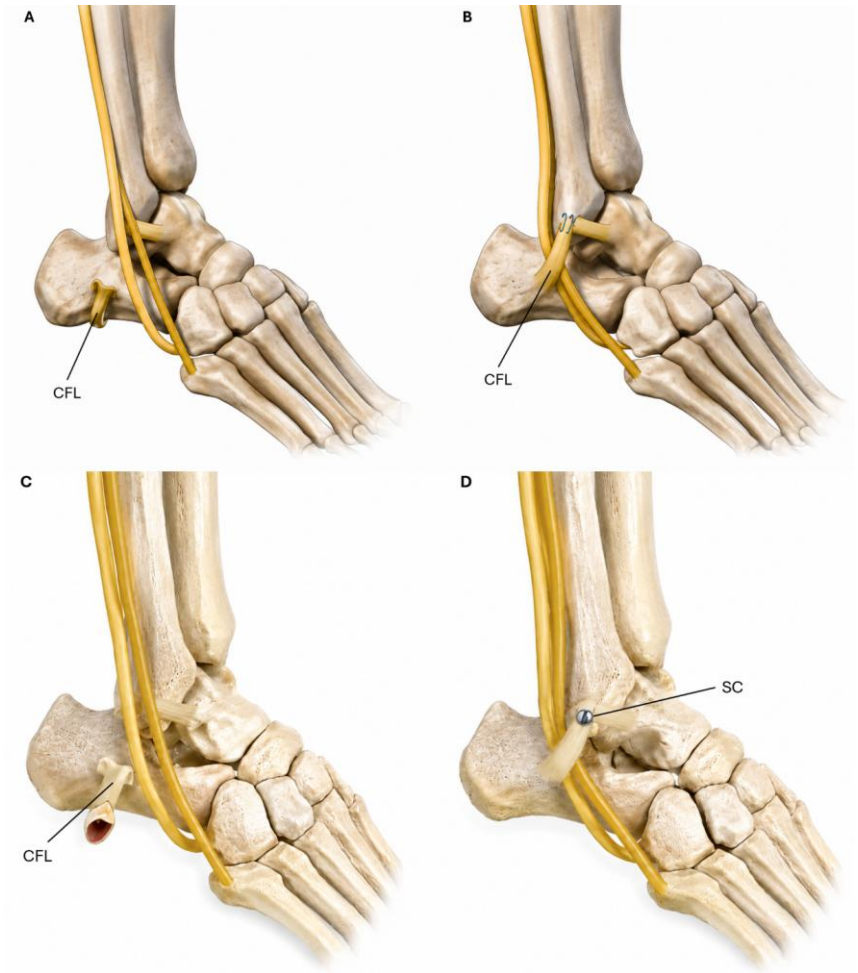


**Figure 8.** Calcaneofibular ligament (CFL) rerouting procedure. (A) The calcaneofibular ligament (CFL) is detached from its fibular attachment. (B) Following reduction of the peroneal tendons, the CFL is rerouted superiorly over the tendons and reattached to its original insertion on the fibula. Alternatively, the CFL may be detached with a small bone block and, after rerouting, fixed back to the fibula using cortical screws to facilitate bone-to-bone healing, as illustrated in (C) and (D).

A modification of CFL rerouting was demonstrated by Pozo and Jackson[61] where the CFL is detached along with the bone by osteotomising the distal fibula (Figure 8C&D) and rerouted over the peroneal tendons for a secure containment and fixed back to the fibula using cancellous screws with the fibula. Similarly, Martens reported a rerouting method by cutting the peroneal tendons (Z – fashion) and taking it under the CFL before repairing it with the tendon sheath and SPR[62].

### 10.2.5 Retromalleolar Groove Deepening and Other Bony Containment Procedures

Groove-deepening procedures are performed to enhance the stability of the peroneal tendons by increasing the depth of the retromalleolar groove on the posterior aspect of the distal fibula, thereby reducing the risk of tendon subluxation or dislocation. As the retromalleolar groove is lined with a fibrocartilaginous surface that facilitates smooth tendon gliding, several techniques have been developed to preserve this fibrocartilage while deepening the groove, rather than removing it through direct bony resection[63]. An arcuate incision was made and the peroneal retinaculum was elevated directly from the fibular margin. If present, the fibrocartilaginous labrum was preserved. Groove deepening is performed by drilling the bone beneath the tendon gliding surface of the retromalleolar groove using a 3.5-mm drill bit to undermine it, with the drill entry placed outside the primary gliding area. Then the retromalleolar groove margins (both medially and laterally) were perforated with a small osteotome on the sides of the groove longitudinally (Figure 9), and the groove was compacted with a wide bone impactor to achieve a deepening of at least 5 mm, while preserving the lateral fibular cortex. Any sharp bony prominences at the fibular tip were removed and smoothened. The retinaculum was then reattached to the new cancellous bone surface using transosseous nonabsorbable sutures (Figure 9Bi)[63]. In a 2-year follow-up study of retromalleolar groove deepening in 23 patients, Walther et al. reported complete recovery in all patients. No local wound complications or recurrence were observed at final follow-up. All patients were permitted to return to full activities at 12 weeks postoperatively[63].

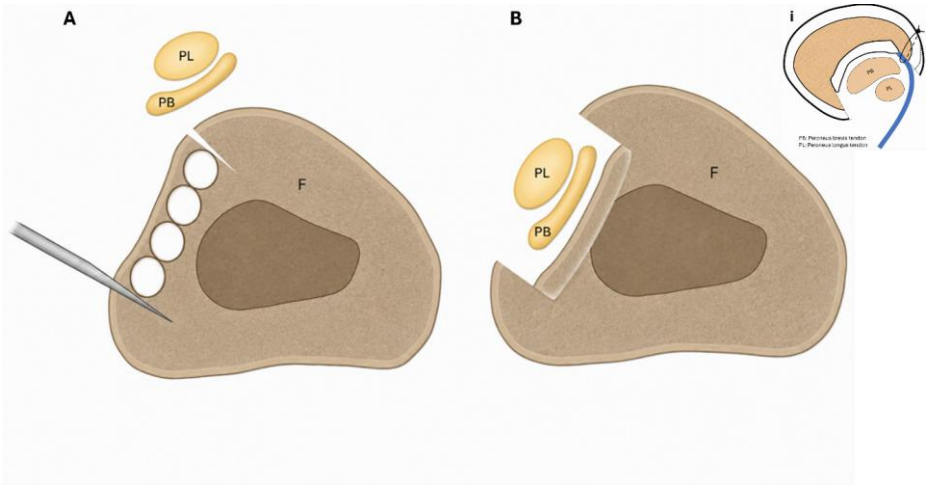


**Figure 9.** Schematic illustration of the groove-deepening procedure. (A) Multiple drill holes are created beneath the articular cartilage of the retromalleolar groove, followed by osteotomies along the medial and lateral margins. (B) The osteochondral flap is impacted to deepen the retromalleolar groove while preserving the articular cartilage, and the SPR is reattached to the new cancellous bone surface using transosseous nonobservable sutures shown in inset (Bi)

*Lateral malleolar osteotomy*

The procedure is considered in cases of shallow or convex retromalleolar groove with chronic instability of the peroneus tendons. A 4–6 cm posterolateral incision over the distal fibula extending approximately 1 cm distal to the fibular tip is made and the SPR false pouch along with the dislocated peroneal tendons were identified. The false pouch was incised, tendon pathology was addressed as required, and tendon tears were repaired with non-absorbable sutures to restore tubular morphology (Figure 10). Associated anomalies, including a low-lying peroneus brevis muscle belly or peroneus quartus, were excised when present. The periosteum was elevated anteriorly while preserving the attachments of the anterior talofibular and calcaneofibular ligaments for resuturing. An oblique osteotomy, directed approximately 20° toward the sagittal plane (Figure 11A), was created from the distal fibula to produce a cortical graft. The graft was translated posteriorly by approximately 3–5 mm and a deep fibular groove is created that provides a mechanical restraint against tendon dislocation. The tendons were reduced anatomically and the graft was secured using absorbable/metal screws while avoiding intra-articular penetration. The SPR and tendon sheath were repaired back to protect the tendons and restore stability[64].




**Figure 10.** Clinical case of peroneus longus tendon dislocation associated with retromalleolar space overstuffing and a shallow retromalleolar groove. (A) Intraoperative image demonstrating a cystic degeneration of the peroneus longus tendon causing overstuffing of the retromalleolar space. (B) Following cyst decompression and tendon repair, retromalleolar groove reconstruction was performed, restoring the tendon to its anatomical position within the groove. (C) Final repair of the superior peroneal retinaculum (SPR) over the fibrocartilaginous ridge (FCR).

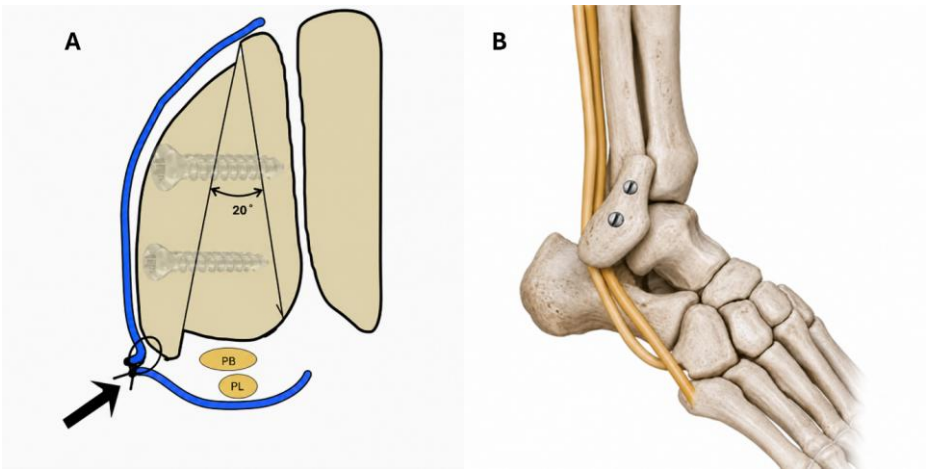


**Figure 11.** Schematic illustration of retromalleolar groove-deepening procedures. (A) Lateral malleolar osteotomy performed at 20°, followed by posterior translation of the osteotomized fragment to deepen the retromalleolar groove with concomitant tightening of the superior peroneal retinaculum (SPR). (B) Kelly's technique, demonstrating posterior rotation of a cortical veneer graft to deepen the retromalleolar groove.

*Kelly's technique*

Through conventional approach and after elevating the SPR with the subluxed tendons posteriorly, a cortico-cancellous veneer graft, approximately 2.5 cm in length, was created from the subcutaneous surface of the distal fibula using sagittal and transverse osteotomies. The graft was then rotated posteriorly such that a translation of approximately 6 mm, preferably in an oblique direction is obtained (Figure 11B), to create a prominent lateral buttress that effectively deepened the retromalleolar groove and prevented anterior displacement of the peroneal tendons. The graft was rigidly secured with two countersunk screws, carefully positioned to maximize fixation within the cortical bone without violating the ankle joint. The periosteum and the SPR were re-sutured opposing the fibular margin[65]. Alternatively a modified techinique was also reported by Micheli et al. in 1989, in which through an extraperiosteal approach, a cortical osteoperiosteal flap is created in the distal fibula in a longitudinal fashion, the flap is translated distally to reconstruct the fibro-osseous tunnel and fixed using cancellous screws[66].

## 11. Conclusions

Peroneus longus tendon dislocation and subluxation are uncommon but clinically important causes of persistent lateral ankle pain, snapping, and instability that are frequently overlooked or misdiagnosed. The condition is best understood as a dynamic failure of the peroneal restraint system rather than an isolated tendon problem. Early recognition through careful clinical assessment and appropriate use of dynamic ultra-

sonography, magnetic resonance imaging, and computed tomography is crucial to prevent chronic dysfunction, tendon degeneration, and delayed treatment. Although several operative strategies are available, the optimal procedure should be individualized based on the chronicity of the symptoms, tendon quality, retinacular integrity, and associated anatomic abnormalities. In general, stable and durable outcomes can be achieved with accurate diagnosis, restoration of tendon containment, correction of predisposing structural factors, and timely rehabilitation.

Current evidence supports surgical management in symptomatic, recurrent, or structurally unstable cases, with satisfactory functional recovery reported after retinacular repair, groove-deepening procedures, and reconstructive techniques. However, important gaps remain regarding isolated peroneus longus pathology, the role of groove morphology, and long-term comparative outcomes across treatment modalities. Further prospective, high-quality studies are needed to refine diagnostic pathways and establish standardized, evidence-based treatment algorithms for this complex condition.

## Declarations

**Ethics approval and consent to participate.** As this manuscript is a review article, ethics approval and consent to participate are not applicable.

**Consent for publication.** As this manuscript is a review article, consent for publication is not applicable.

**Availability of data and materials.** All data and information supporting this narrative review are derived from publicly available published literature cited within the manuscript; no new datasets were generated or analyzed.

**Competing interests.** The authors declare that they have no competing interests for this review article.

**Funding.** This review article and its authors were not funded by any sponsors or corporates.

**Authors' contributions.** Nirmal Nachiketh Binu, Ram Sudhan and Reuel Abraham Kurudamannil devised the idea for the study. Ram Sudhan, Binu Sasidharan, Simran Arora and Said Obied contributed to the literature search. Sahithya Madhusoodanan, Simran Arora and Binu Sasidharan designed and drafted the figures. Nirmal Nachiketh Binu, Ram Sudhan and Said Obied prepared the initial manuscript draft. Ram Sudhan, Reuel Abraham Kurudamannil and Sahithya Madhusoodanan helped with the language and did the proofreading of the article. All authors contributed to, reviewed and approved the final draft of the paper.

**Acknowledgements.** We acknowledge our mentors, supporting staff, librarian, and the subject for their valuable time and willingness to publish this review article.

## References

1. Hosack T, Perkins O, Bleibleh S, Singh R. Snapping ankles: peroneal tendon subluxation and dislocation. Br J Hosp Med. 2023 Oct 2;84(10):1–7. doi:10.12968/hmed.2022.0257

2. Cho E, Perez A, Akwuole F, Pinzur MS, Schiff AP, Hamid KS. Incidence of peroneal tendon dislocation with talus fracture. Foot Ankle Surg Off J Eur Soc Foot Ankle Surg. 2025 Jul;31(5):412–7. doi:10.1016/j.fas.2025.01.002 PubMed PMID: 39843324.
3. Nishimura A, Fujikawa Y, Senga Y, Nakazora S, Konno C, Sudo A. Recurrent peroneal tendon dislocation—the current concept of management. Ann Jt. 2024 Oct;9:40–40. doi:10.21037/aoj-24-10
4. Pellakuru SR, Chapala S, Gupta A, Shirodkar K, Iyengar KP, Metcalfe S, et al. Peroneal tendon anatomy in the retromalleolar region of the ankle: A new radiological classification. J Arthrosc Surg Sports Med. 2025 Apr 29;6:170–3. doi:10.25259/JASSM_8_2025
5. Lootsma J, Wuite S, Hoekstra H, Matricali GA. Surgical treatment options for chronic instability of the peroneal tendons: a systematic review and proportional meta-analysis. Arch Orthop Trauma Surg. 2022 Mar 9;143(4):1903–13. doi:10.1007/s00402-022-04395-4
6. Rosenfeld P. Acute and Chronic Peroneal Tendon Dislocations. Foot Ankle Clin. 2007 Dec;12(4):643–57. doi:10.1016/j.fcl.2007.07.001
7. Rungprai C, Phisitkul P, Femino JE, Martin KD, Saltzman CL, Amendola A. Outcomes and Complications After Open Versus Posterior Arthroscopic Subtalar Arthrodesis in 121 Patients. J Bone Jt Surg. 2016 Apr 20;98(8):636–46. doi:10.2106/JBJS.15.00702
8. Mercer NP, Gianakos AL, Van Dijk P, Mercurio A, Kerkhoffs G, Kennedy JG. Return to Play and Clinical Outcomes in the Surgical Treatment of Peroneal Tendon Dislocation and Subluxation. Foot Ankle Orthop. 2022 Jan;7(1):2473011421S00366. doi:10.1177/2473011421S00366
9. Van Dijk PAD, Vopat BG, Guss D, Younger A, DiGiovanni CW. Retromalleolar Groove Deepening in Recurrent Peroneal Tendon Dislocation: Technique Tip. Orthop J Sports Med. 2017 May 1;5(5):2325967117706673. doi:10.1177/2325967117706673
10. Hallinan JTPD, Wang W, Pathria MN, Smitaman E, Huang BK. The peroneus longus muscle and tendon: a review of its anatomy and pathology. Skeletal Radiol. 2019 Sep;48(9):1329–44. doi:10.1007/s00256-019-3168-9
11. Athavale SA, Swathi, Vangara SV. Anatomy of the Superior Peroneal Tunnel: J Bone Jt Surg-Am Vol. 2011 Mar;93(6):564–71. doi:10.2106/JBJS.J.00662
12. Dangintawat P, Apinun J, Huanmanop T, Agthong S, Chentanez V. New aspect of morphometric study of the superior peroneal retinaculum: pertinent data for surgical repair and reconstruction. Folia Morphol. 2020 Sep 3;79(3):594–603. doi:10.5603/FM.a2019.0120
13. Yokoe T, Tajima T, Ouchi K, Yamaguchi N, Morita Y, Chosa E. Differences in Retromalleolar Fibular Groove Morphology According to Level of Axial Computed Tomography Scans. Orthop J Sports Med. 2024 Mar;12(3):23259671241237255. doi:10.1177/23259671241237255
14. Kumai T, Benjamin M. The histological structure of the malleolar groove of the fibula in man: its direct bearing on the displacement of peroneal tendons and their surgical repair. J Anat. 2003 Aug;203(2):257–62. doi:10.1046/j.1469-7580.2003.00209.x PubMed PMID: 12924825; PubMed Central PMCID: PMC1571151.
15. Hau WWS, Lui TH, Ngai WK. Endoscopic Superior Peroneal Retinaculum Reconstruction. Arthrosc Tech. 2018 Jan;7(1):e45–51. doi:10.1016/j.eats.2017.08.050 PubMed PMID: 29552468; PubMed Central PMCID: PMC5852255.
16. Yammine K. The accessory peroneal (fibular) muscles: peroneus quartus and peroneus digiti quinti. A systematic review and meta-analysis. Surg Radiol Anat SRA. 2015 Aug;37(6):617–27. doi:10.1007/s00276-015-1438-3 PubMed PMID: 25638531.

17. Pesquer L, Guillo S, Poussange N, Pele E, Meyer P, Dallaudière B. Dynamic ultrasound of peroneal tendon instability. Br J Radiol. 2016 Jul;89(1063):20150958. doi:10.1259/bjr.20150958 PubMed PMID: 26943704; PubMed Central PMCID: PMC5257307.
18. Chia CSM, Fu SC, Ko VMC, He X, Zhang X, Hua Y, et al. Investigating peroneus muscle quality in ankle stability: A comparative analysis between chronic ankle instability patients and healthy controls. Phys Ther Sport. 2025 Jul;74:104–17. doi:10.1016/j.ptsp.2025.06.001
19. Abd-Rasid AF, Bajuri MY. Isolated Peroneus Longus Tear - Commonly Missed Diagnosis of Lateral Ankle Pain: A Case Report. Malays Orthop J. 2020 Jul;14(2):130–3. doi:10.5704/MOJ.2007.011 PubMed PMID: 32983388; PubMed Central PMCID: PMC7513650.
20. Little ZE, Kohls J. Peroneal tendon injuries. Orthop Trauma. 2024 Feb;38(1):40–5. doi:10.1016/j.mporth.2023.11.007
21. Davda K, Malhotra K, O'Donnell P, Singh D, Cullen N. Peroneal tendon disorders. EFORT Open Rev. 2017 Jun;2(6):281–92. doi:10.1302/2058-5241.2.160047
22. Eberhard M, Heil P. The Fibular Fleck Sign with Peroneal Tendon Dislocation. Radiology. 2024 May 1;311(2):e232932. doi:10.1148/radiol.232932
23. Lima Cunha R, Castro A, Atilano Carvalho P, Gomes M, Miranda A, Teixeira J. Intrasheath Peroneal Tendon Subluxation: A Report of Three Cases with Technical Note. Rev Bras Ortop. 2024 Dec;59(6):e1003–7. doi:10.1055/s-0044-1779310 PubMed PMID: 39711642; PubMed Central PMCID: PMC11663060.
24. Barbati A, Zoubi M, Marzolini M, Borri M, Iacutone G, Lombardi F. Traumatic peroneal tendon dislocation: a case report and surgical treatment options. Lo Scalpello - Otodi Educ. 2025 Apr;39(1):13–6. doi:10.36149/0390-5276-329
25. Bakker D, Schulte JB, Meuffels DE, Piscaer TM. Non-operative treatment of peroneal tendon dislocations: A systematic review. J Orthop. 2020 Mar;18:255–60. doi:10.1016/j.jor.2019.08.031
26. Qin B, Wu S, Zhang H. Evaluation and Management of Cavus Foot in Adults: A Narrative Review. J Clin Med. 2022 Jun 26;11(13):3679. doi:10.3390/jcm11133679 PubMed PMID: 35806964; PubMed Central PMCID: PMC9267353.
27. Koutsogiannis P, Frane N, Aliyev T, Regala P, Tarazi JM, Bitterman AD. Peroneus Longus and Peroneus Brevis: A Review on Pathology and Updated Treatments. JBJS Rev. 2022 May;10(5). doi:10.2106/JBJS.RVW.21.00238
28. Cates NK, Salerno ND, Kavanagh AM, Schuberth JM, Rubin LG. Peroneal Stabilization Via Tightening of the Peroneal Tendon Sheath. Foot Ankle Spec. 2022 Dec;15(6):566–72. doi:10.1177/19386400211068240
29. Draghi F, Bortolotto C, Draghi AG, Gitto S. Intrasheath Instability of the Peroneal Tendons: Dynamic Ultrasound Imaging. J Ultrasound Med. 2018 Dec;37(12):2753–8. doi:10.1002/jum.14633
30. Eckert WR, Davis EA. Acute rupture of the peroneal retinaculum. J Bone Joint Surg Am. 1976 Jul;58(5):670–2. PubMed PMID: 932065.
31. Oden RR. Tendon injuries about the ankle resulting from skiing. Clin Orthop. 1987 Mar;(216):63–9. PubMed PMID: 3815972.
32. Raikin SM, Elias I, Nazarian LN. Intrasheath Subluxation of the Peroneal Tendons: J Bone Jt Surg-Am Vol. 2008 May;90(5):992–9. doi:10.2106/JBJS.G.00801
33. Mertens K, Vanhoenacker F. The Ankle Fleck Sign Indicating Fibular Avulsion of the Superior Peroneal Retinaculum. J Belg Soc Radiol. 2022;106(1):92.

doi:10.5334/jbsr.2884 PubMed PMID: 36310677; PubMed Central PMCID: PMC9563226.

34. Arthur Vithran DT, Liu X, He M, Essien AE, Opoku M, Li Y, et al. Current advancements in diagnosing and managing cavovarus foot in paediatric patients. EFORT Open Rev. 2024 Jan 9;9(1):69–79. doi:10.1530/EOR-23-0086 PubMed PMID: 38193528; PubMed Central PMCID: PMC10823571.
35. Melville DM, Taljanovic MS, Gimber LH, Miller M, Ahmad A, Sepich D, et al. Comparison of Ultrasound and MRI with Intraoperative Findings in the Diagnosis of Peroneal Tendinopathy, Tears, and Subluxation. J Clin Med. 2024 Jan 27;13(3):740. doi:10.3390/jcm13030740
36. Lee SJ, Jacobson JA, Kim SM, Fessell D, Jiang Y, Dong Q, et al. Ultrasound and MRI of the peroneal tendons and associated pathology. Skeletal Radiol. 2013 Sep;42(9):1191–200. doi:10.1007/s00256-013-1631-6 PubMed PMID: 23685674.
37. Rosenberg ZS, Feldman F, Singson RD. Peroneal tendon injuries: CT analysis. Radiology. 1986 Dec;161(3):743–8. doi:10.1148/radiology.161.3.3786726 PubMed PMID: 3786726.
38. Ohashi K, Sanghvi T, El-Khoury GY, Ahn JM, Bennett DL, Geijer M, et al. Diagnostic accuracy of 3D color volume-rendered CT images for peroneal tendon dislocation in patients with acute calcaneal fractures. Acta Radiol. 2015 Feb;56(2):190–5. doi:10.1177/0284185114522224
39. Taljanovic MS, Alcala JN, Gimber LH, Rieke JD, Chilvers MM, Latt LD. High-Resolution US and MR Imaging of Peroneal Tendon Injuries. RadioGraphics. 2015 Jan;35(1):179–99. doi:10.1148/rg.351130062
40. Stewart ZE, Ghandour S, Mercer RW, Palmer WE, Bejarano-Pineda L. Association of intra-operative findings with MRI observations in patients with peroneal tendon pathology: a blinded retrospective case-control observational study. Skeletal Radiol. 2025 Oct;54(10):2035–43. doi:10.1007/s00256-025-04915-4
41. Ersoz E, Tokgoz N, Kaptan AY, Ozturk AM, Ucar M. Anatomical variations related to pathological conditions of the peroneal tendon: evaluation of ankle MRI with a 3D SPACE sequence in symptomatic patients. Skeletal Radiol. 2019 Aug;48(8):1221–31. doi:10.1007/s00256-019-3151-5
42. Erickson SJ, Cox IH, Hyde JS, Carrera GF, Strandt JA, Estkowski LD. Effect of tendon orientation on MR imaging signal intensity: a manifestation of the “magic angle” phenomenon. Radiology. 1991 Nov;181(2):389–92. doi:10.1148/radiology.181.2.1924777
43. Major NM, Helms CA, Fritz RC, Speer KP. The MR Imaging Appearance of Longitudinal Split Tears of the Peroneus Brevis Tendon. Foot Ankle Int. 2000 Jun;21(6):514–9. doi:10.1177/107110070002100612
44. Wang XT, Rosenberg ZS, Mechlin MB, Schweitzer ME. Normal Variants and Diseases of the Peroneal Tendons and Superior Peroneal Retinaculum: MR Imaging Features. RadioGraphics. 2005 May;25(3):587–602. doi:10.1148/rg.253045123
45. Adachi N, Fukuhara K, Kobayashi T, Nakasa T, Ochi M. Morphologic Variations of the Fibular Malleolar Groove with Recurrent Dislocation of the Peroneal Tendons. Foot Ankle Int. 2009 Jun;30(6):540–4. doi:10.3113/FAI.2009.0540
46. Lotito G, Pruvost J, Collado H, Coudreuse JM, Bensoussan L, Curvale G, et al. Peroneus quartus and functional ankle instability. Ann Phys Rehabil Med. 2011 Jul;54(5):282–92. doi:10.1016/j.rehab.2011.05.004

47. Coleman M, Aziz H, Deveza L, Bradley H, Pettit R, Bahouth S, et al. Pes Cavus and Hindfoot Varus Alignment Are Associated with Increased Rates of Peroneal Tendon Pathology. Foot Ankle Orthop. 2019 Oct 1;4(4):2473011419S00019. doi:10.1177/2473011419S00019
48. Michailidis A, Tsifountoudis I, Kitridis D, Paparoidamis G, Tasoulis K, Makri D, et al. Peroneus brevis tenosynovitis associated with hypertrophied peroneal tubercle: Comparative analysis of 2 cases and their etiologies. Radiol Case Rep. 2026 May;21(5):2235–41. doi:10.1016/j.radcr.2026.02.001
49. Stockton KG, Brodsky JW. Peroneus Longus Tears Associated With Pathology of the Os Peroneum. Foot Ankle Int. 2014 Apr;35(4):346–52. doi:10.1177/1071100714522026
50. Karlsson J, Brandsson S, Kälebo P, Eriksson BI. Surgical treatment of concomitant chronic ankle instability and longitudinal rupture of the peroneus brevis tendon. Scand J Med Sci Sports. 1998 Feb;8(1):42–9. doi:10.1111/j.1600-0838.1998.tb00227.x
51. Tomihara T, Shimada N, Yoshida G, Kaneda K, Matsuura T, Satake S. Comparison of modified Das De procedure with Du Vries procedure for traumatic peroneal tendon dislocation. Arch Orthop Trauma Surg. 2010 Aug;130(8):1059–63. doi:10.1007/s00402-010-1136-x
52. Nishimura A, Nakazora S, Senga Y, Fukuda A, Kato K, Sudo A. Knotless Tendoscopic Peroneal Retinaculum Repair Technique for Recurrent Peroneal Tendon Dislocation. Arthrosc Tech. 2022 Aug;11(8):e1395–401. doi:10.1016/j.eats.2022.03.028 PubMed PMID: 36061466; PubMed Central PMCID: PMC9437467.
53. Park SH, Choi YR, Lee J, Seo J, Lee HS. Treatment of Recurrent Peroneal Tendon Dislocation by Peroneal Retinaculum Reattachment Without Fibular Groove Deepening. J Foot Ankle Surg. 2021 Sep-Oct;60(5):994-997. doi: 10.1053/j.jfas.2020.04.027. Epub 2021 Jun 18. PMID: 34275719.
54. Lui TH, Li CCH. Endoscopic Superior Peroneal Retinaculum Reconstruction Using Q-FIX MINI Suture Anchor. Arthrosc Tech. 2023 Feb;12(2). doi:10.1016/j.eats.2022.11.001
55. Nishimura A, Nakazora S, Ito N, Fukuda A, Kato K, Sudo A. Tendoscopic Double-Row Suture Bridge Peroneal Retinaculum Repair for Recurrent Dislocation of Peroneal Tendons in the Ankle. Arthrosc Tech. 2016 Jun;5(3):e441-446. doi:10.1016/j.eats.2016.01.028 PubMed PMID: 27656359; PubMed Central PMCID: PMC5020598.
56. Ferran NA, Oliva F, Maffulli N. Recurrent Subluxation of the Peroneal Tendons: Sports Med. 2006;36(10):839–46. doi:10.2165/00007256-200636100-00003
57. Hoang TH, Dang HA, Nguyen TCT. Ellis Jones technique as a cost-effective treatment for chronic peroneal tendon subluxation: A case report. Medicine (Baltimore). 2025 Oct 3;104(40):e45139. doi:10.1097/MD.0000000000045139
58. Cao S, Wang C, Wang X, Ma X. Percutaneous Inferior Extensor Retinaculum Augmentation Technique for Chronic Ankle Instability. Orthop Surg. 2022 May;14(5):977–83. doi:10.1111/os.13248 PubMed PMID: 35434967; PubMed Central PMCID: PMC9087451.
59. Wang CC, Wang SJ, Lien SB, Lin LC. A New Peroneal Tendon Rerouting Method to Treat Recurrent Dislocation of Peroneal Tendons. Am J Sports Med. 2009 Mar;37(3):552–7. doi:10.1177/0363546508325924
60. Boykin RE, Ogunseinde B, McFeely ED, Nasreddine A, Kocher MS. Preliminary Results of Calcaneofibular Ligament Transfer for Recurrent Peroneal Subluxation in Children and Adolescents. J Pediatr Orthop. 2010 Dec;30(8):899–903. doi:10.1097/BPO.0b013e3181fbfcea

61. Pozo JL, Jackson AM. A Rerouting Operation for Dislocation of Peroneal Tendons: Operative Technique and Case Report. Foot Ankle. 1984 Jul;5(1):42–4. doi:10.1177/107110078400500106
62. Martens MA, Noyez JF, Mulier JC. Recurrent dislocation of the peroneal tendons: Results of rerouting the tendons under the calcaneofibular ligament. Am J Sports Med. 1986 Mar;14(2):148–50. doi:10.1177/036354658601400210
63. Walther M, Morrison R, Mayer B. Retromalleolar Groove Impaction for the Treatment of Unstable Peroneal Tendons. Am J Sports Med. 2009 Jan;37(1):191–4. doi:10.1177/0363546508324310
64. Zhenbo Z, Jin W, Haifeng G, Huanting L, Feng C, Ming L. Sliding Fibular Graft Repair for the Treatment of Recurrent Peroneal Subluxation. Foot Ankle Int. 2014 May;35(5):496–503. doi:10.1177/1071100714523271
65. Kelly RE. An operation for the chronic dislocation of the peroneal tendons. J Br Surg. 1919 Jan 1;7(28):502–4. doi:10.1002/bjs.1800072808
66. Micheli LJ, Waters PM, Sanders DP. Sliding fibular graft repair for chronic dislocation of the peroneal tendons. Am J Sports Med. 1989 Jan;17(1):68–71. doi:10.1177/036354658901700111

## Authors

**Nirmal Nachiketh Binu**, MBBS, is a medical student at Ras Al Khaimah Medical and Health Sciences University, UAE. ORCID: 0009-0005-9966-2470.

**Dr. Reuel Abraham Kurudamannil**, MD, is a Research Associate at Cleveland Clinic Abu Dhabi, UAE. ORCID: 0000-0002-7189-7535.

**Dr. Binu Sasidharan**, MS Orthopaedics, is a Specialist Orthopaedic Surgeon at NMC Specialty Hospital, Abu Dhabi, UAE. ORCID: 0000-0002-3666-8518.

**Dr. Simran Arora**, MD, is a General Practitioner, University of Debrecen, Debrecen, Hungary. ORCID: 0009-0006-9711-6860.

**Dr. Said Obied**, MBBS, is a Medical Intern at NMC Specialty Hospital, Abu Dhabi, UAE. ORCID: 0009-0009-5443-2697.

**Dr. Sahithya Madhusoodanan Varier** is an MD candidate (year 4) at Nicolae Testemițanu State University of Medicine and Pharmacy, Chișinău, Moldova. ORCID: 0009-0006-5879-8520.

**Dr. Ram Sudhan S**, D'Ortho, DNB (Ortho), MRCPS (Glasg), FIMSA, FAAS, is an Associate Professor at the Department of Orthopaedics, P.K. Das Institute of Medical Sciences, Vaniamkulam, Kerala, India. He is the corresponding author. ORCID: 0000-0002-6327-3861.