Ultrasound protocol for trochlear morphology in children and adolescents

USTM

Niya Gecheva (✉)[1], Alexander Gerchev[1], Valentin Angelov[2], Stefan Tserovski[1]

[1] Medical University Sofia, Department of Orthopedics and Traumatology, Sofia Bulgaria
[2] University Hospital of Orthopedics" Prof. B. Boichev", Sofia, Bulgaria

gecheva_nia@abv.bg

DOI: 10.58542/jbota.v62i1.193

Abstract-- The Aim of our study is to develop and validate a standard ultrasound protocol for trochlear morphology assessment in children and adolescents. The methods we present is non- invasive easy to use instrument for early diagnostics of trochlear morphology specifically in cases of symptomatic knees and patellar instability cases. For the period August 2023 – January 2025 we included 117 children in our study. They underwent prophylactic examination or were evaluated for knee instability, knee pain or documented patellar luxation. Average age of our patients is 14.34 ± 2.58 yrs. In 17 of these cases we documented chondromalacia, in 3 of them – recurrent patellar luxation. For the aim of our study, we used Toshiba Aplio I800 US with linear I24LX8 probe, ultrasound scanning was conducted in 80+ degrees of knee flexion. The results of our ultrasound examination were later compared to X Ray data for 36 patients and MRI data for 7 of them. For the trochlear morphology classification, we used the Dejour classification (A-D). Ultrasound examination showed 11 cases of type A trochlear dysplasia, type B in 4 cases, type D in one case. Comparative analysis with X- Ray and MRI findings demonstrates high level of comparison in trochlear morphology assessment. The ultrasound protocol for trochlear morphology is a reliable and non-invasive method for assessment of trochlear morphology in children in cases of suspected or diagnosed patellar instability. It allows affordable initial diagnosis, especially in pediatric population where we aim to avoid ionizing radiation. We recommend USTM to be integrated with clinical tests and other methods of diagnostics in cases of preoperative surgical planning.

Key words: Ultrasound protocol, trochlear morphology

1. Introduction

The femoral trochlea guides, stabilizes and positions the patella along the movements in the knee joint. In cases of trochlear dysplasia, patellar instability or other pathological conditions this function could be reduced, lost or compromised. Therefore, the shape of the trochlea must be considered when evaluating a patient's risk of instability.[1,2,3] Trochlear dysplasia in paediatric population is traditionally diagnosed using sagittal and axial x-rays as well as axial slices of magnetic resonance images or computed tomography. [4]There are several studies regarding the ultrasound examination of trochlear morphology in children and adolescents. Ultrasound prophylaxis for DDH is standard nowadays, but trochlear morphology is usually assessed only in clinically relevant examination. Trochlear dysplasia is a major cause of patellar instability reported in up to 96% of patients operated on for recurrent patellar dislocations. [3] Although the different predisposing anatomical factors behind patellar instability ity are defined,[4] the aetiology remains unclear. [1,2,3,5]

2. Materials and methods

For a period of 17 months from August 2023 until January 2025 we have examined 117 children with USTM protocol. The average age in our group is 14.34 ± 2.58 years. Patients included in our study group were children addressed for prophylactic examination or clinical conditions – pain, limping, lower leg constitution, instability or documented luxation of the patella. Clinically relevant complains included knee pain, lower extremities fatigue, limping, acute and recurrent patellar luxation. Aim of our study is to asses trochlear pathology and to compare results with other diagnostic examinations- X Ray, CT or MRI if present. One ultrasound scanner was used by two examiners-Toshiba Aplio I800 US with linear I24LX8 probe was used for all patients. The trochlear morphology is assessed by the A-D Dejour classification. Other conditions such as trauma, synovitis or other were not included into our study.

For the aim of the study the patella was positioned in the distal part of the trochlea by flexing the knee over 80°. By holding the transducer in a transverse plane perpendicular to the axis of the femoral axis levelled at the most ventral point of the lateral facet, images of the femoral trochlea were obtained. (Fig.1 A B) Infants were not included as well but we try to assess morphology as well so that we could include it in a future comparison group. Trochlear dysplasia in symptomatic knees with or without recurrent luxation were examined on MRI for treatment plan and preoperative planning. (Fig. 2) The results of our ultrasound examination were later compared to X Ray data for 36 patients and MRI data for 7 of them. For the trochlear morphology.

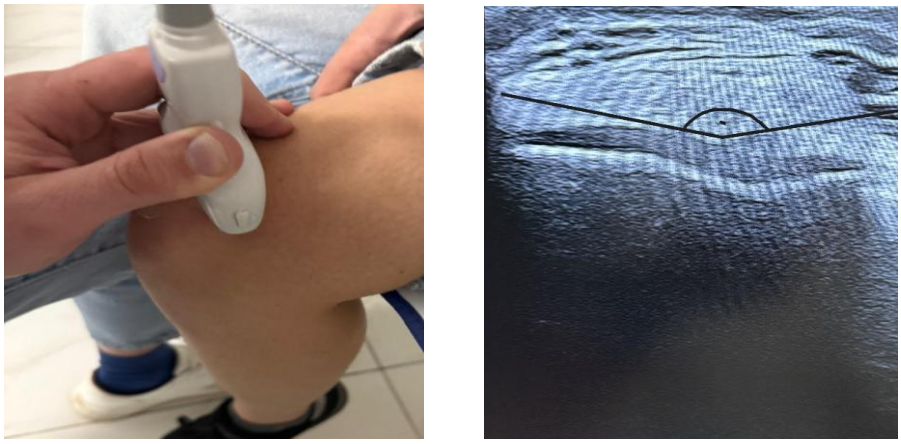

Fig. 1 Probe positioning

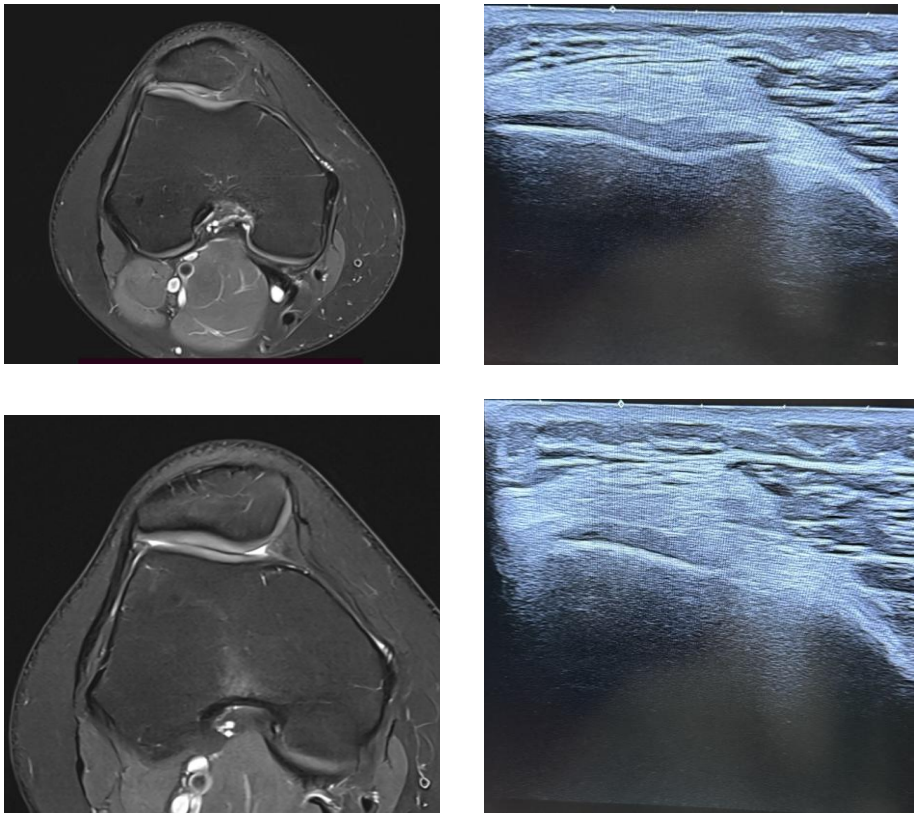

Fig.2 MRI and ultrasound comparison

3. Results

In 11cases patients we suspected trochlear dysplasia type A, type B in 4 cases and 1 case of suspected type D dysplasia.In all these cases we did X-Ray comparison In 17 cases diagnosis was initially summarized as Patellofemoral Pain Syndrome/Chondromalacia based on patient's history and other diagnostic findings. In 3 cases of recurrent luxation type A morphology was observed and later confirmed on MRI. Comparative analysis usings SPSS and non-parametric tests did not show statistically relevant significance of our findings, probably due to the small group of trochlear pathological cases, yet comparison of ultrasound images with MRI shows clinical relevance in all cases. Statistically relevant significance could be only observed in Group A, probably based on the largest number of patients.

4. Conclusion

Looking forward, the application of musculoskeletal ultrasound (MSK US) in the assessment of the femoral trochlea demonstrates considerable potential. Ongoing technological advancements are anticipated to address current methodological limitations, thereby improving image resolution, diagnostic accuracy, and interpretative reliability. Growing interest in femoral trochlear cartilage sonography reflects its established role in the pathophysiology of anterior knee pain, as well as practical considerations, including contraindications to magnetic resonance imaging (MRI) and patient preference for ultrasound as an accessible, cost-effective initial diagnostic modality. Our measurements are consistent with those reported in previous studies employing similar examination techniques. When interpreted in conjunction with complementary clinical findings, such as evidence of patellar instability, this method demonstrates acceptable reliability. Timely and accurate assessment of the femoral trochlea is critical for the early identification and appropriate management of these conditions. The method allows quick access to initial diagnostic especially in paediatric population and athletes.[6] Cartilage echogenicity could be classified in 3 grades, based on a monotonous anechoic band, degenerative changes, loss of the normal sharpness of the cartilage interfaces and/or increased echogenicity of the cartilage especially in cases of chondromalacia.[7] We recommend ultrasound evaluation to be used in combination with other diagnostic procedures in cases of trochlear dysplasia.

5. References

1. Yu KE, Cooperman DR, Schneble CA, et al. Reconceptualization of trochlear dysplasia in patients with recurrent patellar dislocation using 3-dimensional models. *Orthop J Sports Med*. 2022;10:23259671221138257.
2. Schneble CA, Yu K, Venkadesan M, et al. Three-dimensional imaging of the patellofemoral joint improves understanding of trochlear anatomy and pathology and planning of realignment. *Arthroscopy.* 2025;41:130–140.
3. Dejour H, Walch G, Nove-Josserand L, Guier C. Factors of patellar instability: an anatomic radiographic study. *Knee Surg Sports Traumatol Arthrosc*. 1994;2:19–26.
4. Sieberer JM, Park N, Manafzadeh AR, Desroches ST, Brennan K, McDonald C, et al. Visualization of trochlear dysplasia using 3-dimensional curvature analysis in patients with patellar instability facilitates understanding and improves the reliability of the entry point to trochlea groove angle. *Arthrosc Sports Med Rehabil*. 2024;7(1):101010. doi:10.1016/j.asmr.2024.101010.
5. Øye CR, Foss OA, Holen KJ. Minor change in the sulcus angle during the first six years of life: a prospective study of femoral trochlea development in dysplastic and normal knees. J Child Orthop. 2018;12(3):245–250. doi:10.1302/1863-2548.12.180026.
6. Manske RC, Voight M, Page P, Wolfe C. Utilizing MSK ultrasound for comprehensive assessment of the femoral trochlea: a game changer in sports medicine. *Int J Sports Phys Ther.* 2023;18(6):1376–1380. doi:10.26603/001c.90038.
7. Abbasi B, Pezeshki-Rad M, Amini M, Foroughian M, Sahebari M, Nekooei S, Akhvan R. Evaluation of clinical symptoms and sonographic characteristics of femoral trochlear cartilage in primary knee osteoarthritis. *J Emerg Pract Trauma*. 2020;6(1):18–22. doi:10.15171/jept.2019.22.

Authors

Dr. Niya Gecheva, PhD – Assistant Professor Medical University of Sofia. Dr. Gecheva has a PhD entitled “Quality of Life in Children with flat foot deformity.” Dr. Gecheva is in her fifth year of residency at USBALO “Prof. B.Boichev”.

Dr. Alexander Gerchev, PhD – Chief Assistant Professor Medical University of Sofia. Dr Gerchev has a PhD thesis and specialty of Orthopedics and traumatology. MS at University Hospital of Orthopedics USBALO “Prof. B.Boichev”.

Dr.Stefan Tserovski, PhD –Senior Assistant Prof. at Medical University Sofia, Department Orthopedics and Traumatology. Dr Tserovski has a PhD thesis and specialty of Orthopedics and traumatology. MS at University Hospital of Orthopedics USBALO “Prof. B.Boichev”.

Dr. Valentin Angelov - PhD. MD, MBA, MPH. Managing Director at University Hospital of Orthopaedics and Traumatology "Prof.B.Boichev"