Three-Year Randomized Follow-Up of Achilles Tendon Shortening in Prepubertal Children

Niya Gecheva (✉)[1], Alexander Gerchev[1], Stefan Tserovski[1], Valentin Angelov[2], Borislav Chongov[3]

[1] Medical University Sofia, Department of Orthopedics and Traumatology, Sofia Bulgaria
[2] University Hospital of Orthopedics" Prof.B. Boichev", Sofia, Bulgaria
[3] National Sports Academy "Vasil Levski" – Department of Theory and Methodology of Kinesiotherapya, Sofia, Bulgaria

gecheva_nia@abv.bg

DOI: 10.58542/jbota.v62i1.190

Abstract-- Achilles tendon shortening (ATS) is a clinically relevant factor influencing gait mechanics and foot development in childhood. This three-year longitudinal study investigated ATS progression and its biomechanical implications in the same cohort of prepubertal children evaluated annually in 2022, 2023, and 2024. ATS severity was graded using a Silfverskiöld-based protocol, and foot morphology was quantified using the Chippaux–Smirak, Staheli, and Chizhin indices.

Across the follow-up period, ATS exhibited a significant progressive increase (repeated-measures ANOVA $F = 27.69$, $p < 0.0001$), with Tukey post-hoc analysis confirming distinct differences between all assessment years. Concurrently, foot-type distribution shifted toward a greater prevalence of collapsed arches, and chi-square testing demonstrated a moderate but significant association between ATS severity and arch classification ($p = 0.0039$). Gait deviations—including prolonged pronation and altered foot progression angle—were consistent with compensatory adaptations. These findings highlight ATS as a progressive biomechanical modifier during childhood and underscore the importance of early identification and targeted intervention.

Key words: Achilles tendon shortening, cross-sectonal study, flat foot

1. Introduction

Achilles tendon shortening in childhood represents a clinically important condition with the potential to influence gait mechanics, foot posture, and long-term musculoskeletal development. The triceps surae—comprising the gastrocnemius and soleus muscles and inserting via the Achilles tendon onto the calcaneal tuberosity—is responsible for 60–80% of plantarflexion torque during gait, making it the most powerful extrinsic contributor to ankle motion and medial longitudinal arch (MLA) dynamics.[1] A reduction in the functional length of this musculotendinous unit limits ankle dorsiflexion, a movement essential for normal gait. Although reported normative ranges vary widely—from −10° to +22°—most authors cite approximately +10° of dorsiflexion as the minimum required for efficient ambulation. When dorsiflexion is insufficient, the foot and lower limb adopt compensatory mechanisms, which may ultimately predispose to structural deformity.

The relationship between Achilles tendon tension and MLA integrity has been recognized for nearly a century. Keith (1929) proposed that while muscular activity is essential in supporting the arch, ligamentous structures become increasingly important as muscles fatigue under load. [2] Later, Harris and Beath (1948) confirmed that both passive and active stabilizers contribute to arch maintenance and noted a strong association between hypermobile flatfoot and a shortened tendo-Achilles. Their analysis of more than 3,600 Canadian soldiers demonstrated that flatfoot accompanied by tendon shortening tends to progress in severity with age—often mild and functionally silent in childhood, but clinically significant by adolescence and potentially debilitating in adulthood. [3] Electromyographic work by Basmajian and Bentzon further showed that intrinsic and extrinsic muscles such as tibialis anterior and peroneus longus play limited roles in static arch support, whereas tension generated by the triceps surae exerts a pronounced flattening effect on the arch, producing 3.3° of sagittal-plane collapse at 350 N and an additional 3.7° at 700 N, as well as significant forefoot abduction in the transverse plane. [4] This phenomenon is biomechanically intuitive, given that the Achilles tendon inserts posterior to the ankle's axis of rotation, generating an anteriorly directed collapsing force on the MLA.

The pathomechanical role of Achilles tendon shortening in flatfoot development remains highly relevant in pediatric populations. Flatfoot in childhood is often physiologic; however, when accompanied by reduced dorsiflexion, it may alter gait efficiency and cause persistent MLA depression. Myerson emphasized that once calcaneal eversion occurs, the Achilles tendon's line of pull shifts lateral to the subtalar joint axis, increasing the pronatory moment on the hindfoot. This mechanism amplifies arch instability, particularly during the stance phase when the foot transitions from a flexible shock absorber to a rigid lever for propulsion. [5] In severe or longstanding cases, the combination of Achilles tendon contracture and MLA collapse can lead to substantial functional impairment. These compensatory movements place excessive strain on the foot's intrinsic support components and diminish the effectiveness of its stabilizing structures, contributing to progressive structural deterioration.

Despite the established biomechanical principles, longitudinal clinical studies investigating the progression of Achilles tendon shortening in prepubertal children remain scarce. A multi-year follow-up provides insight into whether Achilles tendon shortening is stable, progressive, or self-limiting during periods of rapid growth, and whether its presence correlates with the onset of flatfoot deformity.

2. Materials and methods

This three-year prospective cohort study evaluated changes in Achilles tendon length in prepubertal children and examined the relationship between tendon shortening and foot posture. All methodological procedures followed the standardized clinical protocol presented at the 2025 National Congress of the Bulgarian Orthopaedics and Trauma Association. The same cohort of school-aged children was evaluated annually between 2022 and 2024, resulting in sample sizes of 355 children in 2022 (192 male and 163 females), 556 children in 2023 (289 male and 267 females), and 545 children in 2024 (281 male and 264 females). The mean age of the cohort across the assessments was approximately 10 ± 1.26 years. All examinations were performed in the same orthopedic department by the same clinical team to minimize inter-examiner variability.

Clinical evaluation of Achilles tendon shortening (ATS) was conducted bilaterally through standardized ankle dorsiflexion testing with both knee-extended and knee-flexed positions, following the principles of the Silfverskiöld test, which distinguishes isolated Achilles tendon tightness from combined gastrocnemius–soleus contracture. During all measurements, the subtalar joint was carefully positioned in neutral alignment to prevent compensatory pronation from artificially increasing dorsiflexion. Achilles tendon shortening was classified using a four-grade clinical system, where Grade 0 denoted no shortening, Grade 1 mild shortening, Grade 2 moderate shortening, and Grade 3 severe shortening. **(Fig.1)**

A subset of measurements was gathered using the Zebris FDM plantar pressure analysis system, where digital definitions of CSI, SAI, and the Chizhin Index were adapted for improved measurement precision. Foot posture was evaluated under full weight-bearing. The Chippaux–Smirak Index (CSI) was calculated as the ratio of the narrowest midfoot width to the forefoot width multiplied by 100, with values of 0.1–29.9% classified as normal arches, 30–50% as lowered arches, and 50–100% as flatfoot. **(Fig.2)** The Staheli Arch Index (AI) was calculated as the ratio of the midfoot width to the heel width, with 0.5–0.7 indicating normal arch and 0.7–1.2 indicating flatfoot. The Chizhin Index was based on geometric division of the footprint into medial and lateral components (I = EF/FG), where values <1 indicated a normal arch, 1–2 a lowered arch, and >2 a flatfoot. **(Fig.3)** These indices were selected because they provide reliable, reproducible structural characterization of the medial longitudinal arch and have been validated in recent pediatric studies.

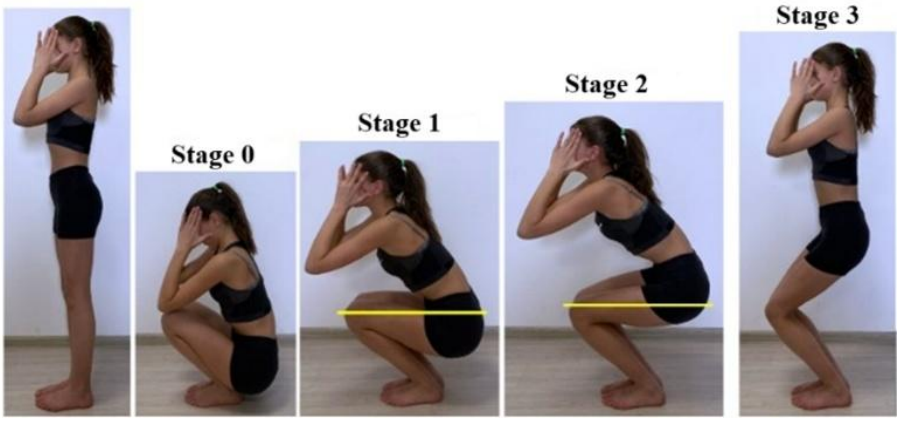

Fig. 1 Stages of the Achilles tendon shortening

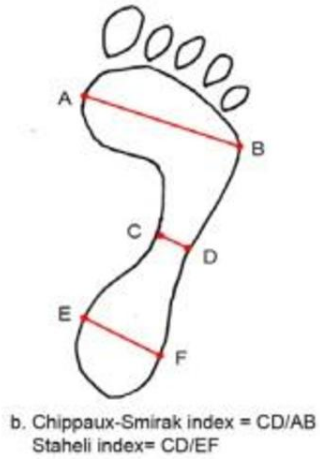

Fig.2 CSI and AI indices measurement

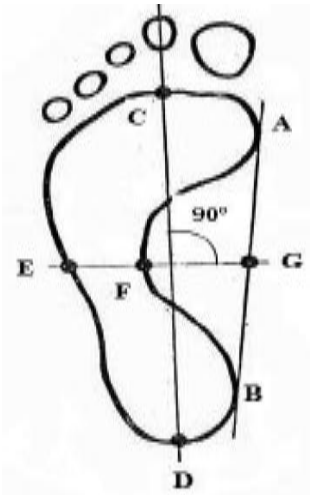

Fig.3 Chizhin index

3. Results

The foot-type distribution demonstrated notable shifts over the three-year follow-up period. In 2022, most children presented with a normal medial longitudinal arch (61.1%), while collapsed arches accounted for 30.4% and flatfoot for only 8.5% of the cohort. By 2023, the proportion of normal arches declined significantly to 43.2%, accompanied by a marked increase in collapsed arches to 47.1%. Flatfoot prevalence in-

creased slightly to 9.7%, maintaining its status as a minority finding. In 2024, the distribution remained similar to the previous year, with 44.0% of children exhibiting normal arches and 49.0 % demonstrating collapsed arches, while flatfoot decreased to 7.0%. **(Table. 1)**

Year	**Foot type**	0.0	1.0	2.0	3.0
2022	NF	171	21	17	4
2022	Collapsed arch	93	13	6	2
2022	**FF**	**19**	**7**	**1**	**1**
2023	NF	**240**	51	31	9
2023	Collapsed arch	111	37	25	22
2023	**FF**	**17**	**6**	**3**	**4**
2024	NF	201	79	55	23
2024	Collapsed arch	69	19	24	13
2024	**FF**	**24**	**5**	**7**	**7**

Table.1 Distribution of the foot type during the three years of the study

To evaluate whether Achilles tendon shortening (ATS) changed significantly across the three examination years, a one-way analysis of variance (ANOVA) was performed. This statistical method is appropriate when comparing the means of more than two independent groups—in this case, the mean ATS scores for 2022, 2023, and 2024. ANOVA tests the null hypothesis that all group means are equal, and a statistically significant F-value indicates that at least one year differs from the others.

In this study, ANOVA produced a highly significant F-value of 27.69 with a p-value < 0.0001, demonstrating that the mean level of Achilles tendon shortening varied strongly across years and that these differences were extremely unlikely to be due to random variation.

Because ANOVA reveals only that differences exist—but does not identify which years differ—a Tukey HSD (Honestly Significant Difference) post-hoc test was employed. Tukey's test is a conservative multiple-comparison procedure that controls for Type I error while performing all pairwise comparisons between years. It calculates a mean difference for each pair, along with a confidence interval and an adjusted p-value. **(Table. 2)**

	Square sum	**DF**	**F-value**	**p-value**
Year	44.56	2	27.69	**< 0.0001**
Error (Residual)	1153.88	1434	-	-

Table. 2 Results from ANOVA analysis showing very high F-value (27.69), which means that the differences between the years are significant.

The Tukey analysis confirmed that all three pairwise comparisons were statistically significant ($p < 0.05$):

- 2022 vs. 2023 already showed a meaningful increase in tendon shortening,
- 2022 vs. 2024 showed the largest change, with a mean difference of 0.4582, and
- 2023 vs. 2024 remained significant, indicating continued progression.

The consistency of statistical significance across all comparisons confirms a linear, progressive trajectory of Achilles tendon shortening across the three-year period rather than a one-time change or fluctuation. Together, the ANOVA and Tukey HSD analyses provide strong statistical evidence that Achilles tendon shortening increases systematically over time in this cohort.

In the context of this study, the chi-square (χ^2) test was applied to evaluate whether Achilles tendon shortening is related to foot type. The test revealed a statistically significant association between ATS and foot type ($p = 0.00388631$), confirming that tendon shortening correlates with the presence of lowered arch or flatfoot deformity. However, the strength of this relationship remained moderate, supporting the view that ATS is a contributing factor within a broader multifactorial process of arch development and collapse. **(Fig. 4)**

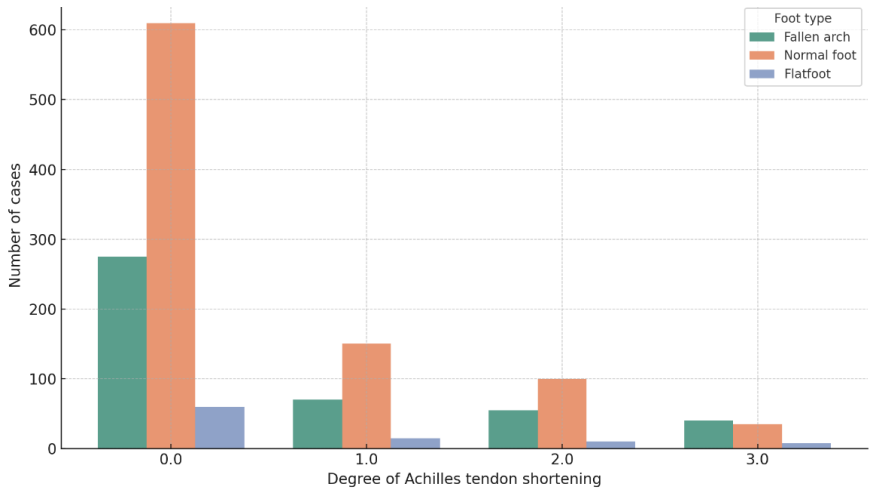

Fig. 4 Distribution of Achilles tendon shortening by foot type

4. Discussion

Gait is commonly defined as a bipedal, biphasic forward propulsion of the human body's center of mass, produced through sequential sinusoidal movements of multiple segments with minimal energy expenditure. In other words, gait represents the coordinated movement pattern of the limbs, whose primary function is to ensure locomotion, propulsion, and support of the body. [6] Against this biomechanical backdrop, the present study examined how progressive Achilles tendon shortening (ATS) influences foot posture and gait characteristics in prepubertal children over a three-year follow-up period.

Our findings revealed a consistent and significant increase in ATS severity across the study period, with ANOVA results confirming meaningful differences between all years and Tukey analysis showing the most pronounced change between 2022 and 2024. Mild, moderate, and severe shortening all increased, reflecting a shift toward higher grades as children aged. The chi-square test further showed that ATS was significantly associated with foot type, although the relationship was moderate in magnitude. Children with mild and moderate ATS were more likely to exhibit a collapsed arch.

The biomechanical mechanisms underpinning these findings correspond closely with established literature. In human walking, muscles regulate angular momentum by accelerating body segments and generating ground-reaction forces that maintain dynamic stability. The triceps surae plays a central role in this regulation: its eccentric action modulates tibial advancement during early stance, while its concentric action drives propulsion. When its length is reduced, dorsiflexion becomes limited, prompting compensatory strategies to maintain forward progression. Clinically, foot pronation is recognized as a common adaptation to insufficient dorsiflexion. Gross (1995) proposed that excessive excessive toe-out foot placement angle possibly leading to abnormal weight bears and alter plantar loading. [7]

During the normal gait cycle, weight acceptance begins with initial contact, typically a heel-strike pattern in healthy individuals. At this moment, internal tibial rotation occurs concurrently with eversion of the hindfoot, mediated through the coupled motion of the subtalar, talonavicular, and calcaneocuboid joints. Simultaneously, the tibiotalar joint plantarflexes, allowing controlled lowering of the foot to the supporting surface. Ground-reaction forces acting at heel strike also induce a transition in the anterior crural muscles—from concentric to eccentric activation—thereby providing controlled deceleration of the foot and preventing uncontrolled plantarflexion. This coordinated eccentric activity across the anterior and posterior crural compartments attenuates impact forces and facilitates a smooth transition into the loading response and subsequent midstance phases of gait. During midstance, forward progression of the body induces external tibial rotation and ankle dorsiflexion, prompting posterior-tibialis–driven hindfoot inversion that locks the midtarsal joint, restores medial arch tension, and converts the foot into a rigid lever for propulsion. [8] However, as Inman et al. (1981) demonstrated, with the knee extended the gastrocnemius increases the ankle flexion moment by about 30%, generating higher tension through the Achilles tendon. [9] Because the Achilles tendon inserts posterior to the ankle's axis of rotation, increased tension shifts

the center of pressure anteriorly across the MLA, reducing heel loading and precipitating premature heel rise. Our results showing progressive ATS parallel this mechanism: as ATS severity increased, children showed greater reliance on pronation-based compensation.

Gastrocnemius inflexibility exerts its greatest influence during midstance, the period during which the body progresses over the stationary foot. [10] This is also the moment when the gastrocnemius reaches its maximal functional length. Passive stiffness in this phase can alter ankle kinetics and ground reaction force profiles, increasing pronation and forefoot abduction. Our results demonstrated early heel rise, increased pronation, and altered foot progression angle—findings entirely consistent with these biomechanical expectations.

The distinction between elastic and rigid gastrocnemius contracture, described by Perry & Burnfield (2010), further contextualizes our observations. Children in our study exhibited adaptive gait patterns rather than pathological toe walking, indicating predominantly elastic inflexibility. Elastic contracture allows near-normal heel-strike due to tissue elongation under load, whereas rigid contracture results in equinus gait and forefoot strike. [11]

This redistribution of plantar loading has been documented clinically. Aronow et al. (2006) demonstrated that increased triceps surae tension shifts plantar pressure from the hindfoot toward the midfoot and forefoot, increasing vulnerability to valgus collapse. [12] Interventions that reduce triceps surae tension have been shown to reverse these patterns. Clinical findings by Hill (1995) and Downey & Banks (1989) further support that even in non-neurological cases, lengthening of the gastrocnemius or soleus improves gait mechanics and foot function. These clinical observations lend strong external validity to our finding that ATS progression correlates with increased arch instability. [13,14]

Gait analysis studies provide additional support. Twomey & McIntosh (2012) found that children with low arches adopt subtle but effective gait compensations, including increased external hip rotation, without significant temporo-spatial deficits. Kothari et al. (2016) similarly reported altered ground reaction force patterns and reduced push-off efficiency in children with flatter arches, supporting our interpretation that ATS progression influences both foot and proximal joint mechanics. [15,16]

Taken together, our results demonstrate that Achilles tendon shortening is a progressive, clinically relevant factor influencing gait mechanics and foot posture in growing children. Although ATS alone does not predict flatfoot, it contributes significantly to arch destabilization, prolonged pronation, and altered stance-phase kinematics. Nonetheless, the cumulative effect of progressive shortening across the three years highlights the importance of early monitoring particularly in children exhibiting collapsed arches or functional gait adaptations.

5. Conclusion

This three-year analysis shows that Achilles tendon shortening in prepubertal children progresses measurably and exerts a significant influence on foot mechanics. Increasing ATS severity correlates with higher rates of medial arch collapse and with characteristic compensatory gait adaptations driven by restricted dorsiflexion. Although not a primary cause of flatfoot, ATS acts as an important functional modifier of load distribution and kinematics in the developing foot. These findings underscore the need for early identification and biomechanically targeted management strategies.

.

6. References

1. Sale D, Quinlan J, Marsh E, McComas AJ, Belanger AY. Influence of joint position on ankle plantarflexion in humans. J Appl Physiol. 1982;52(6):1636–1642. DOI: 10.1152/jappl.1982.52.6.1636
2. Keith A. The history of the human foot and its bearing on orthopaedic practice. J Bone Joint Surg. 1929;11:10–13.
3. Harris RL, Beath T. Hypermobile flatfoot with short tendo Achilles. J Bone Joint Surg Am. 1948;30:116–140.
4. Basmajian JV, Bentzon JW. An electromyographic study of certain muscles of the leg and foot in the standing position. Surg Gynecol Obstet. 1954;98:662–666.
5. Myerson MS. Adult acquired flatfoot deformity: Treatment of dysfunction of the posterior tibial tendon. J Bone Joint Surg Am. 1996;78:780–792.
6. Perry J. Gait Analysis: Normal and Pathological Function. Thorofare (NJ): SLACK Incorporated; 1992.
7. Gross MT. Lower quarter screening for skeletal malalignment—suggestions for orthotics and shoewear. J Orthop Sports Phys Ther. 1995; 21:389–405. DOI: 10.2519/jospt.1995.21.6.389
8. Van Boerum DH, Sangeorzan BJ. Biomechanics and pathophysiology of flat foot. Foot Ankle Clin. 2003; 8:419–430. DOI: 10.1016/s1083-7515(03)00084-6
9. Inman VT, Ralston HJ, Todd F. Human Walking. Baltimore (MD): Williams & Wilkins; 1981.
10. Orendurff MS, Segal AD, Aiona MD, Dorociak RD. Triceps surae force, length and velocity during walking. Gait Posture. 2005; 21:157–163. DOI: 10.1016/j.gaitpost.2004.01.009
11. Baddar A, Granata K, Damiano DL, Carmines DV, Blanco JS, Abel MF. Ankle and knee coupling in patients with spastic diplegia: effects of gastrocnemius–soleus lengthening. J Bone Joint Surg Am. 2002;84:736–744. DOI: 10.2106/00004623-200205000-00006
12. Aronow MS, Diaz-Doran V, Sullivan RJ, Adams SB. The effect of triceps surae contracture force on plantar foot pressure distribution. Foot Ankle Int. 2006;27(1):43–52. DOI: 10.1177/107110070602700108

13. Hill RS. Ankle equinus: prevalence and linkage to common foot pathology. J Am Podiatr Med Assoc. 1995;85(5):295–300. DOI: 10.7547/87507315-85-6-295
14. Downey MS, Banks AS. Gastrocnemius recession in the treatment of nonspastic ankle equinus: a retrospective study. J Am Podiatr Med Assoc. 1989; 79:159–174. DOI: 10.7547/87507315-79-4-159
15. Twomey DM, McIntosh AS. The effects of low arched feet on lower limb gait kinematics in children. Foot (Edinb). 2012;22:60–65. DOI: 10.1016/j.foot.2011.11.005.
16. Kothari A, Stebbins J, Zavatsky AB, Theologis T. Health-related quality of life in children with flexible flatfeet: a cross-sectional study. J Child Orthop. 2014;8:489–496. DOI: 10.1007/s11832-014-0621-0

Authors

Dr. Niya Gecheva, PhD – Assistant Professor Medical University of Sofia. Dr. Gecheva has a PhD entitled “Quality of Life in Children with flat foot deformity.” Dr. Gecheva is in her fifth year of residency at USBALO “Prof. B.Boichev”.

Dr. Alexander Gerchev, PhD – Chief Assistant Professor Medical University of Sofia. Dr Gerchev has a PhD thesis and specialty of Orthopedics and traumatology. MS at University Hospital of Orthopedics USBALO “Prof. B.Boichev”.

Dr.Stefan Tserovski, PhD –Senior Assistant Prof. at Medical University Sofia, Department Orthopedics and Traumatology. Dr Tserovski has a PhD thesis and specialty of Orthopedics and traumatology. MS at University Hospital of Orthopedics USBALO “Prof. B.Boichev”.

Borislav Chongov - Specialist in kinesiotherapy with PhD.He works at the National Sports Academy "Vasil Levski" in the Department of Theory and Methodology of Kinesiotherapy, and also at the University Hospital of Orthopedics “Prof. B.Boichev”.

Dr. Valentin Angelov - PhD. MD, MBA, MPH. Managing Director at University Hospital of Orthopaedics and Traumatology "Prof.B.Boichev"