CONFUSIONS AND CONVICTIONS IN THE PLACEMENT OF ACETABULAR CUP IN THA – A BRIEF ANALYSIS OF THE PAST, PRESENT AND FUTURE

Ram Sudhan S[1], Muhammed Faisal[2], Abdul Gafoor PM[3], Muhammed Fazil V V[4], Anwar Marthya Hamid[5], Sharat Balemane[6], Fardeen Shariff [7]

[1] PK DAS Institute of Medical Sciences, Vaniamkulam, Ottapalam, Kerala, India
[2,3,4,5] IQRAA International Hospital and Research Centre, Kozhikode, Kerala, India
[6,7] Yenepoya Medical College Hospital, Deralakatte, Ullal, Karnataka , India

sudhansubramaniam@gmail.com

DOI: 10.58542/jbota.v62i1.170

Abstract— Total hip arthroplasty is a highly successful surgery done worldwide in case of irreversible joint destruction of the hip due to various causes such as arthritis (osteoarthritis, rheumatoid arthritis, post-traumatic), septic sequelae and dysplasia to alleviate pain and regain motion. The success depends on the precise placement of the implants, especially the acetabular cup, which is technically demanding with a higher margin of error. Incorrect cup placement may decrease range of motion, psoas and bone impingement, edge loading, accelerated component wear, leg length discrepancies, and increased risk of dislocation and may result in early prosthesis failure and subsequent revision. Historically, many landmarks. methods and concepts were followed to orient the cup in the desired position both in coronal and sagittal planes with the help of universally accepted parameters like inclination, anteversion, horizontal offset, vertical offset and acetabular offset, yet it is still ambiguous as the intraoperative positioning is practically challenging. Thus, with the advent of newer technologies and evolution of concepts, this review sums up the path in its entirety by consolidating the works of quality literature.

Keywords-Total hip arthroplasty, acetabular cup placement, Navigation, Robotics, Anteversion, Inclination

1. Introduction

With patient satisfaction rates over 90%, many consider total hip arthroplasty (THA) the most effective surgical procedure in this century. Globally, osteoarthritis of the hip is a major cause of pain and overall disability[1]. In 2019, the annual volume of THA done worldwide was 2,62,369 with a growth rate of 5.2% and is expected to increase

by 28.84% every 5 years[2]. Precise placement of the implant is necessary to get optimal outcomes[3]. Decreased range of movements (ROM), impingement, edge loading, component wear, alterations in leg length, and increased risk of dislocation might occur due to incorrect cup placement, which may lead to early prosthesis failure and subsequent revision[4].

Version and inclination (abduction) are the primary variables used to characterize the cup's location. The version refers to the cup's sagittal plane orientation. Greater anteversion permits greater hip flexion and adduction before impingement. Conversely, a lower ante version or retroversion is associated with a greater chance of posterior dislocation, while a higher ante version may increase the risk of anterior dislocation[5]. The cup's orientation in the anteroposterior plane (coronal) is known as its inclination. A higher inclination, or a vertical cup at its maximum, causes less surface area to meet the upper cup dome, which might lead to increased contact stress, which might accelerate implant deterioration. Conversely, low inclination restricts the range of motion by causing early impingement, particularly during abduction.

Historically, Lewinnek et al.'s 1978 definition of the "safe zone" has served as a reference for cup placement[6]. To reduce the possibility of dislocation, a zone with a 30–50° inclination and a 5–25° anteversion was suggested. The question of complication rate, especially dislocation, when placed outside this range, remains ambiguous with mixed data[7]. Several minor modifications of the safe zones have been reported throughout time. Most techniques, according to Weber et al., are unable to overcome the problem of impingement[8]. They recommended narrower safe zones, the most effective range being 40–50 degrees of tilt and anteversion, ranging from 20 to 30 degrees[9]. The notion of a combined ante version, which incorporates ideas such as patient-specific target zones or stem implantation, which were also proposed by other authors.

Placing the cup in the right place may be difficult, even without considering the debate about precise values and individual safe zones. While most instances result in the goal zone being achieved, even highly skilled surgeons report notable outliers[10], which is due to problems in identifying anatomic landmarks caused by soft tissue contractures, anatomic variations related to hip dysplasia, or anatomic modifications resulting from osteophytes or prior trauma[11]. Some of the other reasons for component malposition include patients with dysplastic hips, morbidly obese patients, performing surgery on the non-dominant side, and low-volume surgeons[8].

It is debatable to what degree the surgical technique influences the precision of cup placement. When compared to posterior or lateral approaches, certain studies indicated reduced dislocation rates and better outcomes in THA done through the direct anterior approach[12]. Conversely, other authors, regardless of approach and methods, observed similar outcomes[13]. However, in the direct anterior approach, being patient lying supine on the operating table, the use of intraoperative fluoroscopy becomes simpler, easier, and more precise.

Furthermore, it is currently recognized that acetabular component location measurement using simple radiographs might be imprecise. Computerized navigation is being

used in THA to enable accurate positioning of the femoral and acetabular components within the intended functional zones, allowing for less invasive evaluation of limb length changes. Using preoperative and intraoperative images provides more accurate orientation even in dysplastic hips[14].

These computer-assisted systems show promising results in improving the precision of cup orientation (i.e., 93% lying within the desired Lewinnek safe zone, while it is 43 to 73% in the conventional freehand arthroplasty. Also, 80 to 93% lie within the safe zone while using an image-free navigation system, and 83 to 100% of hips with a CT–based navigation system[15,16]. Also, the dislocation rates, which are 0-8 % in the free-hand technique, are significantly improved to 0% in image-free navigation systems and 0- 0.5 % with CT-based navigation systems[17].

In brief, the main technical goals of total hip arthroplasty (THA) are to restore native hip mechanics and achieve precise implant positioning. As a result of advancements in surgical technology, computer navigation and robotics have been developed to increase precision in cup placement, besides decreasing human error. In this new technical era, using computer guidance for navigation in the placement of cups has attracted greater interest in the milieu of precise cup placement to avoid the foresaid difficulties and complications. Thus, this narrative aims to provide an overview of the available technologies, emphasizing computer navigation in acetabular cup placement in a collective nutshell, amalgamating the standard works of literature.

2. CUP POSITIONING TECHNIQUES

A brief scheme and rational approach for the acetabular cup in THA is interpolated in **Figure 1** for better understanding and interpretation, irrespective of the methods of placement. From here, we begin the elaboration of cup placement methods to make the reader appreciate and recognize what to achieve and how to achieve systematically.

3. ANATOMIC LANDMARK-BASED FREEHAND POSITIONING

Anatomical landmarks may be used to guide the positioning of acetabular components. A number of reference points are specified, including the transverse acetabular ligament, the anterior and transverse acetabular notch, the frontal pelvic plane (created by the spines of the upper ilia and the pubic tubercles)[18].

Positioning the acetabulum referencing the TAL: Archbold et. al in their study mentioned that it may be possible to place the cup in the anteversion inside the safe zones without further guidance if the inferomedial rim is parallel to the transverse acetabular ligament (Figure 2) and found a dislocation risk of 0.6% when using a posterolateral technique[19]. In their study, Molho et al. found that when TAL is used as a reference for anteversion and inclination, 100% of the hips were inside the safe zone, and 90% of the hips were within the safe zone, respectively[20].

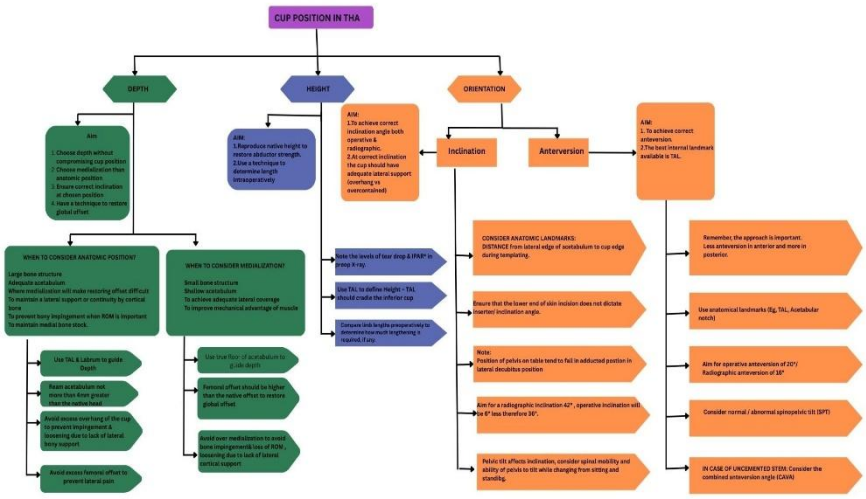

Figure 1: Approach to acetabular cup position in THA

Mechanical alignment rod along with TAL as reference: The transverse acetabular ligament (TAL) may complement the alignment rod technique and provide acetabular component position (Figure 3). With the use of TAL reference, Kelley and Swank[21] discovered that 82% and 71% of their cups were located inside the safe zones that Lewinneck had identified for inclination and anteversion, respectively. This improves the mechanical alignment rod results.

In a follow-up investigation including 121 THA patients, including those with dysplastic hips and primary osteoarthritis, by using computer navigation, the cup was positioned, and it was evaluated to see how well TAL aligned with the trial acetabular component. They found that the proportion of natural TAL locations against the computer-navigated trial acetabular component, lying outside the safe zone, was less than 5%[22].

Limitations: According to the findings of Ling et al[23], However, cup implants at higher inclinations outside the safe zone were more common in pelvises with sagittal backward malrotation (pelvic roll back). As they demonstrated the optimal posture by anatomical landmarks, which lead to a posture beyond the safe zone when evaluated on postoperative radiographs because the pelvis rolls back physiologically, which increases the inclination that appears in standard radiographs.

Most surgeons use intraoperative alignment jigs concerning the patient's position on the operating table while placing the acetabular component. In the lateral position, the

patient's superior shoulder is often used to measure the cup's anteversion and inclination from the floor. It is now understood, although, that it is challenging to determine the exact position of the patient's pelvis while lying on the table. The pelvis' orientation concerning the patient's body or the table is a critical criterion and should not be heedless. The pelvis may bend forward by up to 35 degrees, and the lumbar lordotic curve flattens in the lateral position[24]. Moreover, the acetabulum's superior aspect may be inclined by 10 to 15 degrees in the direction of the table's foot end. As a result, cups that are positioned using alignment jigs may end up being too vertical and retroverted. Digioia et al. (2002)[25] provided more evidence of the broad diversity of mechanical acetabular alignment guidelines in the lateral position. Due to significant heterogeneity in pelvic position, they found that 78% of the acetabular components implanted with mechanical alignment guides had imprecise alignment.

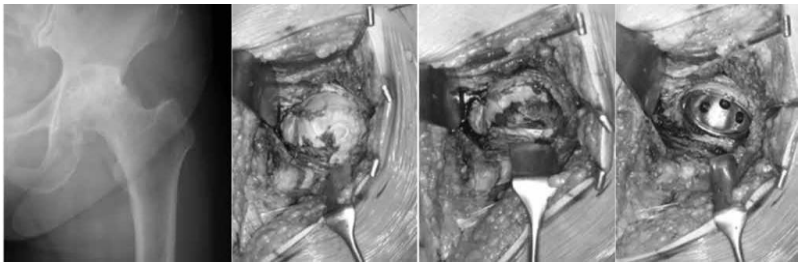

Figure 2: A: Radiograph of hip with primary osteoarthritis (Crowe grade-1 dysplastic), B: showing osteophytes covering transverse acetabular ligament (TAL), C: osteophyte removed by a chisel, and D: with acetabular cup placed parallel to the TAL.

Figure 3: Setup showing the pelvic saw bone mounted in the sagittal plane with TAL parallel to the floor and a cup held in the acetabulum with a mechanical alignment guide (MAG) attached to the cup handle. (a) the standard MAG with its horizontal limb parallel to the floor. (b) the modified MAG with a spirit level attached, which can be leveled in two planes.

4. ALIGNMENT USING INTRAOPERATIVE FLUOROSCOPY

It is common to find intraoperative fluoroscopy in the orthopaedic theatre setup. As the patient is supine during the anterior approach to THA, it is simpler to use fluoroscopy intraoperatively to control component location. Stereometric effects, often known as parallax, may affect angle measurement and cause inconsistencies in the use of fluoroscopy during surgery and the use of radiographs taken thereafter[26].

***Alignment using plain fluoroscopy*:** Using the method that was outlined by Tannast et al.[27], Boettner and Rueckl discovered that intraoperative fluoroscopy offers a reliable method for measuring inclination about the inter-teardrop line, provided the pelvic tilt on the OT table was also taken into account. It was proposed by the authors that a correction factor of 5 degrees be used to compensate for the parallax while evaluating the intraoperative C-arm tilt. The fluoroscopy model (company or make) can also directly affect this 5° correction factor. Based on anteroposterior pelvic radiographs, different techniques were devised to produce cup anteversion. It has been demonstrated that the techniques outlined by Lewinnek, Hassan, and Liaw are trustworthy. But their applicability is limited since they need precise measurements "on film" with standardized AP radiographs, which shall be done using computer software or a ruler.

According to Boettner and Zingg[28], there is a unique approach to determining cup anteversion that makes use of the tilt angle of the C-arm. This method comprises the following three stages: Firstly, to get a view of AP pelvis, both the obturator foramen needs to be symmetrical, and the sacrum's center must line up with the pubic symphysis, avoiding rotation errors **(Figure 4).** Secondly, the C arm is placed exactly over the center of the hip, and then gradually tilted away from the side that is being operated on until the cup's equatorial plane(rim) is at right angles to the receptor of the C-arm **(Figure 5).** Finally, take a direct reading on the C arm to calculate the tilt angle, which matches the anatomic anteversion angle[29]. When compared with CT readings, there was an average of 0.2° higher (with a range of 3.0°to 3.1°) anteversion obtained by this method. All cups were placed within the safe zones that were defined, with an average anteversion and inclination of 40.8° and 18.4°, respectively.

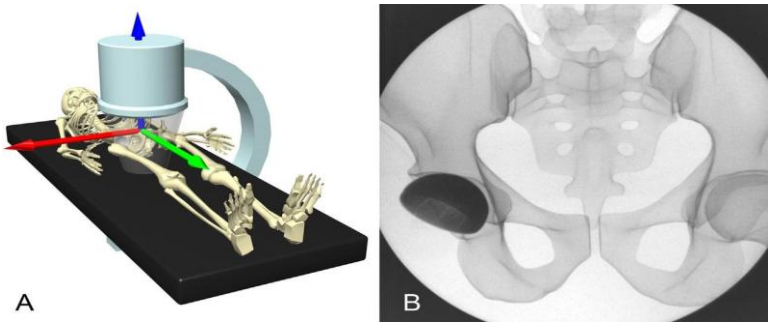

Figure 4: (A) The fluoroscopy is kept at right angles to the operating table. (B) The acetabular cup rim appears elliptical on anteroposterior pelvic view.

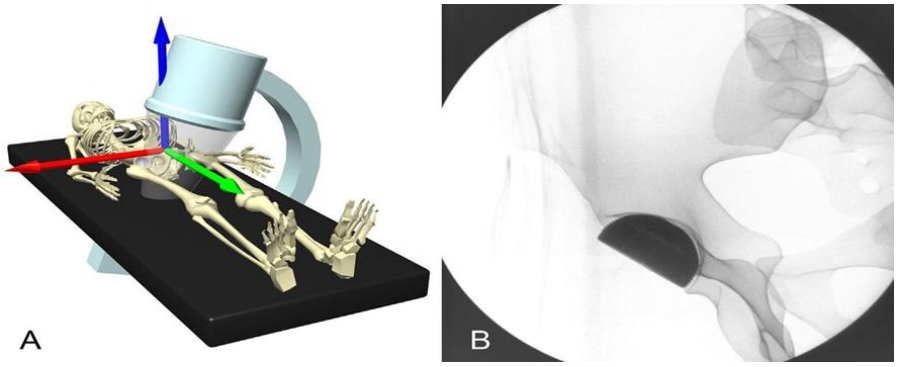

Figure 5: (A) The fluoroscopy is adjusted such that the image amplifier lies perpendicular to the plane of the acetabular cup rim, so that (B) the acetabular rim appears linear due to superimposition and no longer elliptical.

***Alignment using fluoroscopy image and iPad application[30]*:** In this method, the fluoroscopy image is uploaded to an application to get an interpretation about the parameters of the acetabulum. Using fluoroscopy screenshots of images taken in Ipad, a five-step process is used to determine intraoperative inclination, anteversion, and global offset. Before surgery, the target anteversion and inclination are set in the iPad application. After exposure and reaming, the cup is first temporarily fixed, and an AP pelvis fluoroscopy image is taken (with neutral rotation of pelvis and adjusting the pelvic tilt), the screenshot of which is cropped to fit the previously specified parameters in the application on iPad, the software projects an inclination reference line over the image (Figure 6a), based on which the inclination of the component can be changed accordingly. Similarly, the targeted cup opening (anteversion) is projected over the fluoroscopy AP image on Ipad to guide the surgeon and final impaction is made. Final check is made by calculating the tilt angle of the C-arm for anteversion and inter teardrop reference line for inclination (Figure 6a). Leg length discrepancy can be checked by taking a second AP fluoroscopy image and calculating the distance between a reference line and a fixed point in the lesser trochanter (Figure 6b) and comparing with the other hip after fixation of the femoral component. Both the intraoperative results and the postoperative radiographs for anteversion and inclination revealed a mean difference of 1.0◦ and 1.2◦, respectively, with no significant statistical difference[30].

***Alignment using fluoroscopy grids[31]*:** The primary limitation of fluoroscopy in cup placement is peripheral image distortion, which may provide inaccurate information when evaluating intraoperative component placement. To address this, a novel grid (either manual or digital) of known dimensions can be used. This may also avoid parallax and can immediately measure the location of the component that is being placed. The manual grid was fastened to the fluoroscopic receiver and wrapped in standard sterile fluoroscopic drapes prior to the surgery (**Figure 7).**

Figure 6: The inter-tear drop horizontal reference line is used to measure (A) the cup inclination and (B) the vertical offset by the distance between the lesser trochanter and the inter-tear drop line.

In contrast, digital grid systems have computer computer-generated projection of grid patterns over fluoroscopic images through which modifications can be performed (Figure 8). The intrinsic 45° line enables tailored tilt of cup position, while the grid lines enable visual measurement of LLD and offsets. After trial reduction, LLD and offsets were evaluated by properly aligning the grid's trans-teardrop reference line with the pelvic landmarks and comparing both sides **(Figures 7 and 8).** Intraoperative cup abduction was validated by referencing the 45°gridlines present on the grid.

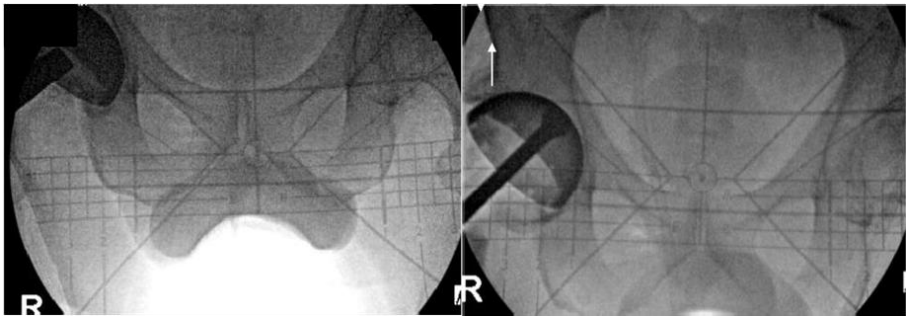

Figure 7: Fluoroscopic images of the manual grid system in which (A) the leg length discrepancies and the global hip offset can be assessed using the grid reference line at the bottom. (B) The inclination of the acetabular cup can be determined concerning the inter-teardrop line in the grid. Note: Due to image distortion in fluoroscopy, subtle distortion of the grid line is apparent.

Figure 8: Fluoroscopy images of the digital grid system in which (A) the leg length discrepancies and the global hip offset are assessed similarly using trans-teardrop reference line at the bottom. (B) shows cup inclination guides, with the dotted reference line indicating 40° inclination and the adjacent reference lines indicating 35°and 45° as well. Note: There is no gridline distortion due to the digital image correction factor.

Compared to intraoperative fluoroscopy alone, the adjustable fluoroscopic grid improved component position accuracy and precision with 97% of acetabular cup abduction angles placed within the target zone and 100% of leg length discrepancies and 85% of global hip offsets differences measured under10mm. Additionally, 82% of components met all three targeted goals while decreasing surgical times when using the grid to supplement plain fluoroscopy[32].

Limitation: The inability to make intraoperative modifications, which necessitated patient repositioning to match with the grid, was a major limitation of the original prototype grid. This method only works in the supine position (anterior approach)[31].

5. PATIENT-SPECIFIC INSTRUMENTATION[33]

Computer-assisted surgery techniques are evolving to make surgical procedures more accurate. Recently, patient-specific guides have been developed for cup placement, designed from pre-operative CT-scans. With a Non-contrast CT (1mm cut) of the pelvis with bilateral hips, images were imported to Mimics' software (version 17.0) and a virtual 3D model of the pelvis with subtracted femur was generated. The diameter of the unaffected acetabulum on the normal side was taken as the cup size. A jig (with a handle and a ring) based on the size of the measured diameter of the contralateral acetabulum was virtually created and mirrored such that it fits the peripheral rim of the acetabulum on the side to be operated. It is then 3D printed in polylactic acid (PLA) material (Figure 9a). The 3D-printed jig was autoclaved and used as a guiding tool for cup placement. The jig is placed over the postero-superior aspect of the acetabulum with the help of a plate attached to the jig through K-wires (Figure 9b). After the cup is properly seated, the ring portion of the jig surrounds the posterosuperior rim of the acetabulum in the appropriate anteversion and inclination as a reference for guiding the

cup placement. Then, using the jig as a guide for orientation, the acetabulum was reamed and the acetabular cup was positioned.

The clinical benefit of the jig was that the mean anteversion and inclination angle of all the cups fixed using the patient-specific jig lay within the safe range and showed less variability with fewer outliers than the freehand technique. It is more useful, especially when the anatomical landmarks are altered, as in malunited acetabular fractures and bony ankylosis of the hip. These are expensive alternatives that require more soft tissue dissection with relatively larger exposure around the acetabulum, which may increase the surgical time and might pose a surgical complexity to achieve accuracy, especially in obese and high BMI individuals.

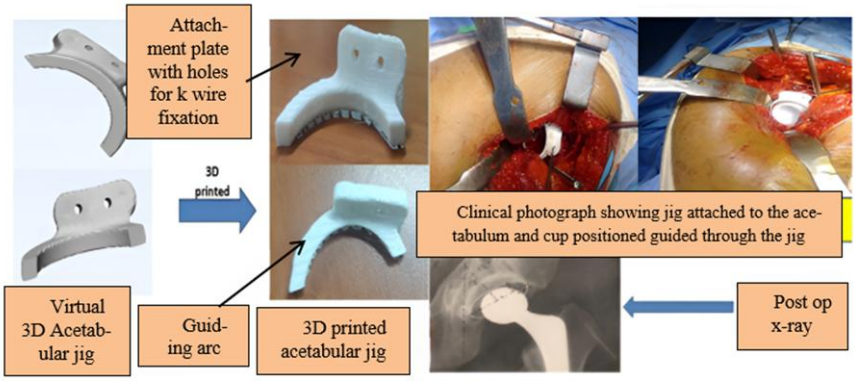

Figure 9: (A) shows the virtual image of the jig and the 3D printed jig. (B) Placement of the jig intraoperatively and the postoperative image[33]

6. 3D MINI-OPTICAL NAVIGATION SYSTEM[34]

Mini navigation system may serve as the basis for navigation. The system includes a camera, a probe, and a tracker, all located inside the sterile field, and an outside monitor with a workstation. The device uses integrated microelectronics, infrared light, and optical technologies to gather real-time data regarding cup position and sends it to a workstation that is visible to the surgeon but outside the sterile field. A tracker antenna is first inserted into the anterior superior iliac crest and greater trochanter on either side by the surgeon to determine the anterior pelvic plane or supine coronal plane in either lateral decubitus or supine position, respectively. Registration requires the use of a probe to identify the anatomical landmarks like ASIS, symphysis pubis, and pubic tubercle for mapping. Data like size, depth, offsets, inclination, and anteversion are displayed on the workstation monitor and are available to the surgeon in real-time for reference at any time throughout the surgery. Real-time anteversion and inclination data can be obtained by attaching the tracker to the cup impactor after acetabular reaming **(Figure 10)**. Trial reductions and final cup placement, including leg length measurements, may

all be viewed, measured, and saved appropriately for future modifications as necessary. The mean difference between measured inclination of the system impactor and target inclination was 0.65°± 0.32(range: 0.15°–1.25°) is similar and positively correlates *r*=0.99 with the measurements obtained by the navigation tool against the reference target. These results demonstrated that the device measures the known target values of offset and cup position, including leg length, accurately within the range of 1° and 1 mm, respectively. Limitations include image artifact, intraoperative patient movements, rotation of the pelvis in radiographs, and imaging artifact, which may affect the measurements obtained during the procedure.

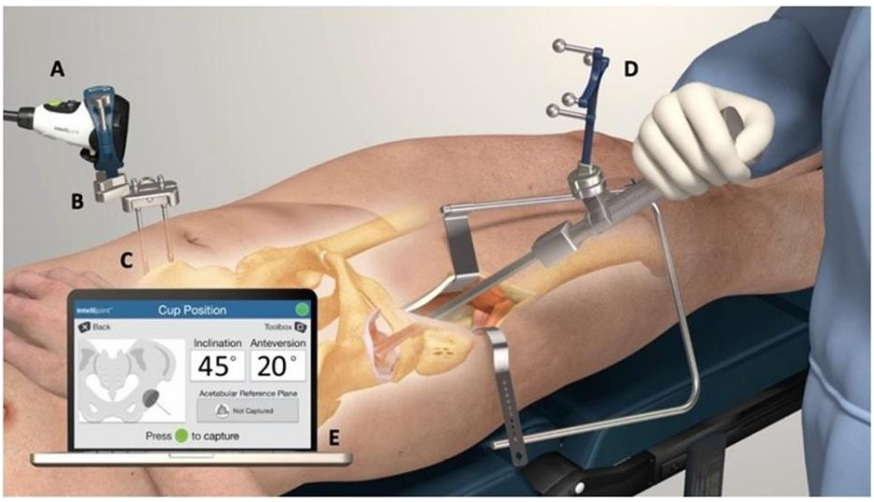

Figure 10: Using 2 pelvic screws (C), the pelvic platform(B) is rigidly fixed, such that camera (A) aligned over the pelvic platform is stable. A device tracker (D) is fastened to the impactor using a magnet. After registration of the native orientation of the acetabulum, the camera captures the positional changes of the trial component via the impactor, which is relayed to the workstation (E). (Intellijoint HIP® 3D mini-optical navigation tool, Intellijoint Surgical, Inc., Waterloo, ON, Canada)[34]

7. ACCELEROMETER-BASED NAVIGATION SYSTEM[35]

The accelerometer-based navigation (New HipAlign) system consists of a disposable navigation unit, a display console, and reference sensors. Accelerometers (triaxial) and gyroscopes within the navigation unit and reference sensors relay with each other wirelessly. The reference sensors and the navigation unit were connected, and target values were preset before surgery. Under sterile precautions, using two Schanz pins (3.2 mm) and one oblique pin on the iliac crest, the metal pelvic base is connected, on which the navigation unit is fastened. **(Figure 11).** Registration of the body in the cor-

onal plane is done using a probe parallel to the long axis of the table. The system calculates the reference plane from the coronal registration and gravity. The inclination, anteversion, and leg length were measured using a laser beam projection from laser module to the reference sensors placed in the cup impactor (for inclination and anteversion, **figure 11a**) and the greater trochanter and distal femur (for leg length, **figure 11b**) appropriately. The limb length is measured with the limb in its neutral reference position, which is at 0° of internal/external rotation, flexion, and abduction. The target inclination and anteversion are set on the display console. The impactor with the reference sensor is moved appropriately to accomplish the target angle of the acetabular cup for fixation.

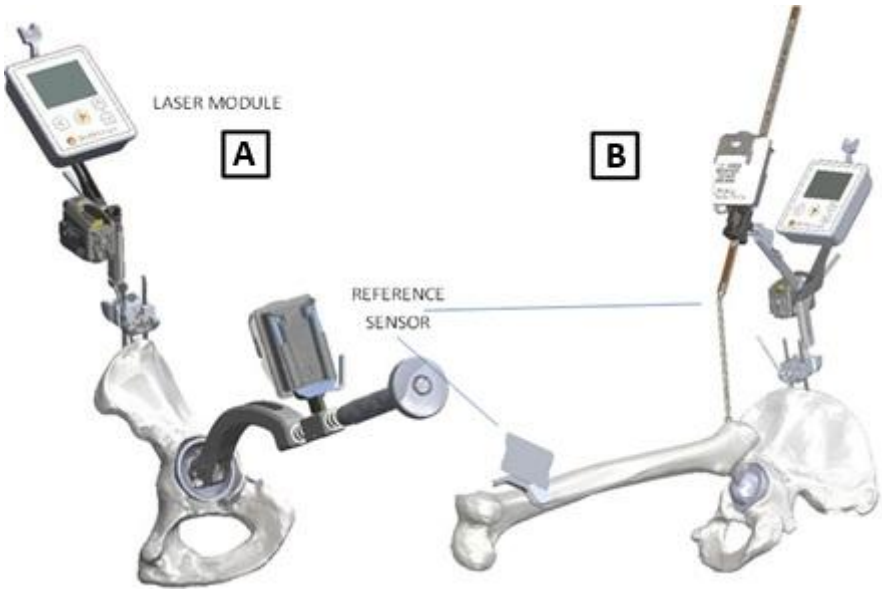

Figure 11: shows the accelerometer-based navigation system. (A) The reference censor is fixed to the impactor through which the inclination and anteversion of the acetabulum are estimated. (B) shows the presence of a reference sensor on the greater trochanter and distal femur through which the leg length discrepancies are estimate[35].

Postoperatively, the absolute deviation of the measured angles from the target position for the cup inclination and cup anteversion was 3.7° ± 3.3° (range, 0° to 14.0°) and 5.9° ± 3.6° (range, 0.2° to 13.3°), respectively. The mean accuracy in measuring limb length was 0.8 ± 3.4mm (range, 8 to 10 mm).

8. COMPUTER NAVIGATION AND TOTAL HIP ARTHROPLASTY

Computer navigation is appropriate for hip arthroplasty because precise goals have been established for component location. Since the acetabular component's orientation is probably the most important factor in a successful hip arthroplasty, it is not surprising that computer guided acetabular placement has attracted most attention in literature. Since 1992, computer navigation systems have been used in hip replacements[36]. There are two methods of positioning the cup via computer navigation: imaging systems and systems that do not use images (imageless).

For the proper operation of image-based navigation systems, morphological data must be gathered either by intraoperative fluoroscopy (as seen in Figure 12) or preoperative CT or MRI scans. In imageless navigation systems, intraoperative data of anatomic landmarks is added to a computer-generated representation of the human body's structure and function[37]. Imageless systems are the ones most often employed in clinical settings, according to published navigation studies. As shown in Figures 14 and 15, these systems are built on virtual pictures. Both systems aim to provide surgeons with real-time feedback and make pre-operative planning possible through a readout tab or head-up display.

Imageless Systems*:* These systems rely on locating the bony landmarks in the pelvis which gives inputs to the sensors on the reamer of the patient's pelvic location about the anterior pelvic plane **(Figure 13).** Regardless of the commercial system being used, a four-stage procedure that consists of setup, registration, planning, and execution phases has been defined.

For the computer to detect the pelvic orientation in space, registration of anatomical landmarks is a prerequisite in computer-assisted navigation for the placement of the acetabular component. Usually, to do this, registration is done at the pubic tubercle, symphysis pubis, and the anterior superior iliac spines. A pelvic view from the front, which is utilised to reference cup position, is formed by referencing these features. Optical trackers affixed to the pelvis are used for registration in imageless systems as seen in Figure 3. Particularly when the patient is planned for the procedure in lateral decubitus position the optical pointer is positioned to record the pubic tubercle, symphysis pubis and the anterior superior iliac spines before positioning using tiny incisions after palpating anatomical landmarks appropriately[38,39]. The patient is given anesthesia throughout the ‘setup’ and ‘registration’ phases in the operating room. The ‘true version plane’ of the acetabulum is identified using the transverse acetabular ligament (TAL) as a reference point. To get the correct acetabular inlet plane, the superior acetabulum and the TAL are recorded together. Literature has criticized both systems for putting the surgical team and patients through more preparatory time and expense, as well as radiation.

Based on the information provided by Lewinnek, it was determined that 82% of the acetabular cups were positioned within the safe zone of inclination, while 71% were

positioned within the safe zone of anteversion[40], according to Kelley and Swank's (2009) findings. While the mean of the acetabular cup's inclination and anteversion did not differ statistically between the conventional and group that used navigation had less variation in cup placement and a low risk of placing the acetabular cup placement outside of the safe zone, according to a new meta-analysis and systematic review of 400 patients[21]. According to this review's analysis of the available research, navigation is a trustworthy method for maximizing cup placement and reducing outliers. However, before firm conclusions about the usefulness of regular navigation in THA can be made, long-term results and cost-utility studies are required.

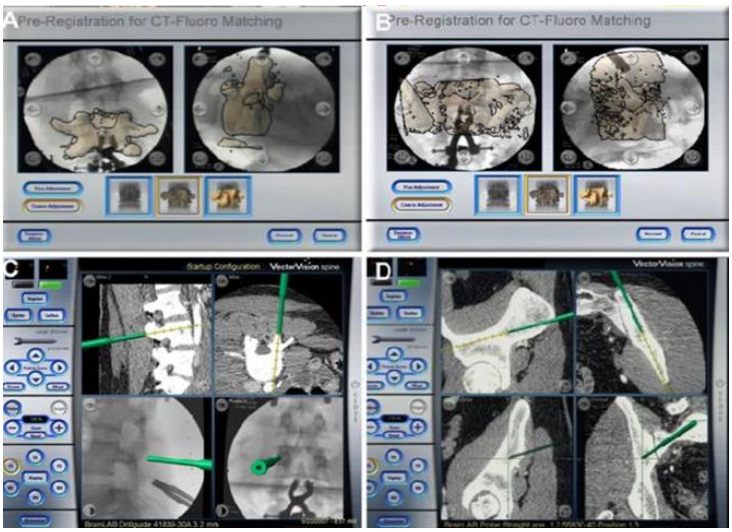

Figure 12: shows monitor screenshots of image-based navigation systems (registration, matching, and intra-operative real-time pictures)



Figure 13: Registration of bony landmarks in imageless systems shown on a dry-bone model with a sensor on a mock reamer.

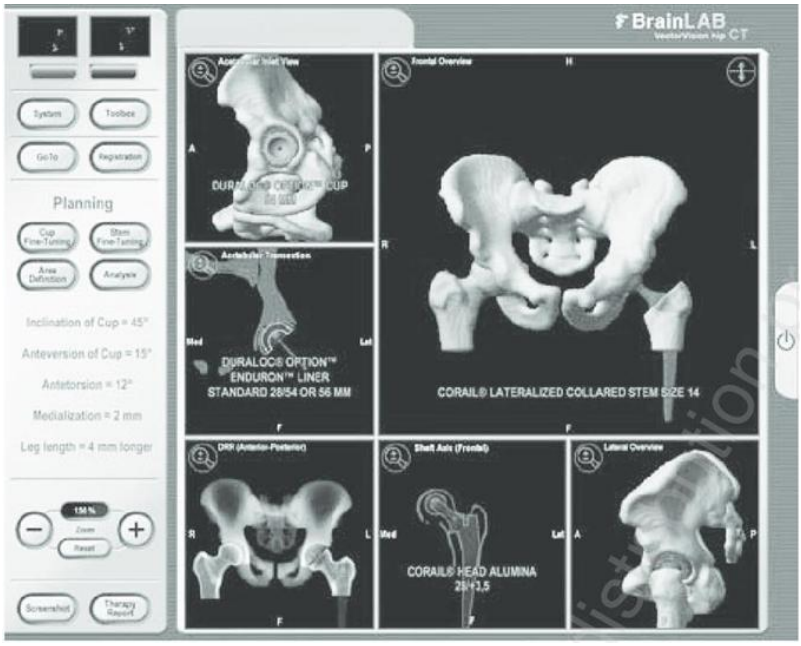

Figure 14: screenshot of imageless navigation virtual picture of monitor showing window of preoperative planning after registration.

Figure 15: workstation monitor of the imageless navigation system showing the reference line guides of the acetabular inclination and anteversion. (Image courtesy of Inline Orthopaedics)

9. ROBOTICS IN TOTAL HIP ARTHROPLASTY

A robot is a computerized electronic machine devised to execute a variety of mechanical functions which are programmed. The biotechnology of robotics is used in the planning and positioning of the acetabular cup and femoral stem. Three types of systems based on principles, mechanism of action and execution methods are defined:

1. passive systems: (Ex da Vinci surgical system)
2. Semi-Active system: that controls the hand of the surgeon in real time. (robotic arm-assisted surgery)
3. Active System:(THINK Surgical, CUVIS) can able to do tasks independently without any human assistance or direction using pre-programmed algorithms and a set of specified guidelines for bone resection.

Also, three types of executing and/ or cutting methods are developed[41].

1. Autonomous: The resection of bone is done without any human intervention.
2. Haptic control: requires human interaction to manoeuvre the robot; the movement of the robot is constrained by a set limit[42].
3. Boundary control: the system is not constrained and surgeon handles the robot, the robot action can be deactivated or stopped if the bone resection exceeds the planning limits (Smith nephew, Ex Navio surgical system).

Similar to the other navigation systems, Robotic THA also involves registration of bony landmarks, verification by the system (where, if the error is >1mm, re-registration is required), mapping, followed by data display on a monitor **(Figure 16)**. which, when verified by the surgeon fed to the execution unit of the robotic arm. The execution of the function can be of two types, (A) The express procedure: in which the size of the femoral stem, neck cut, and size are to be planned by the surgeon while the size acetabular cup and placement are assisted. (B) The enhanced procedure, which offers the facility of navigation for femoral osteotomy and version with implantation of the stem, in addition to sizing and placement of the acetabular cup. With a single reamer size, the acetabulum is reamed using a robotic-assisted arm based on the preoperative planning that regulates and limits the operative surgeon's hand in progression of reamer, orientation of cup and stem, centre of rotation, and during impaction of the cup. Various adjustments can be made at different time points as the system permits trial checking and re-adaptation of planning during surgery[43]. The success and outcomes after robotic THA are driven by multiple factors, including the precision and reproducibility of the placement and complications, bone stock management of combined anteversion, learning curve, system adaptability irrespective of the patient's anatomy and

morphology, benefits in complication rates with functional outcomes, compatibility with ambulatory care and enhanced recovery post-surgery, and assessment of cost-effectiveness [43].

The use of robotics is beneficial with clear evidence in accurate positioning of implant with minimal resection of bone and in regulating the femoral version, sizing of stem and neck, besides maintaining appropriate limb length, thereby allowing early and better functional outcomes, enhancing patient's recovery. Robotics also presents several limitations in routine application concerning universal usage in all hip morphologies, in addition to its availability and ease of access across all institutions[43].

Similar to the other navigation systems, Robotic THA also involves registration of bony landmarks, verification by the system (where, if the error is >1mm, re-registration is required), mapping, followed by data display on a monitor (Figure 16). which, when verified by the surgeon fed to the execution unit of the robotic arm. The execution of the function can be of two types, (A) The express procedure: in which the size of the femoral stem, neck cut, and size are to be planned by the surgeon while the size acetabular cup and placement are assisted. (B) The enhanced procedure, which offers the facility of navigation for femoral osteotomy and version with implantation of the stem, in addition to sizing and placement of the acetabular cup. With a single reamer size, the acetabulum is reamed using a robotic-assisted arm based on the preoperative planning that regulates and limits the operative surgeon's hand in progression of reamer, orientation of cup and stem, centre of rotation, and during impaction of the cup. Various adjustments can be made at different time points as the system permits trial checking and re-adaptation of planning during surgery[43]. The success and outcomes after robotic THA are driven by multiple factors, including the precision and reproducibility of the placement and complications, bone stock management of combined anteversion, learning curve, system adaptability irrespective of the patient's anatomy and morphology, benefits in complication rates with functional outcomes, compatibility with ambulatory care and enhanced recovery post-surgery, and assessment of cost-effectiveness[43].

The use of robotics is beneficial with clear evidence in accurate positioning of implant with minimal resection of bone and in regulating the femoral version, sizing of stem and neck, besides maintaining appropriate limb length, thereby allowing early and better functional outcomes, enhancing patient's recovery. Robotics also presents several limitations in routine application concerning universal usage in all hip morphologies, in addition to its availability and ease of access across all institutions[43].

Figure 16: Shows robotic-assisted systems used for THA (CUVIS). A: monitor and sensor console, B: the robotic arm

10. DISCUSSION

After Total hip arthroplasty, leg length discrepancies may be a factor in impaired hip function. Leg length disparity has been linked to abnormal gait, discomfort, neurological dysfunction, and patient discontent, among others. In comparison to freehand methods, Manzotti et al.[44] (2009) demonstrated that a computer-controlled system could provide noticeably superior leg lengths. Nevertheless, there was no considerable variation in the two groups' functional outcomes according to this research. Minimally invasive surgery has several benefits over standard procedures in THA, such as low blood loss, less discomfort, reduced hospital stays, decreased rehabilitation time with less scarring and eventually speedy recovery. The best way to take advantage of computerized navigation's precision seems to be minimally invasive surgery. It is inherently more challenging to place components using freehand approaches due to the narrower operational field[45].

When TAL was used as a reference for positioning the acetabular component, Archbold et al. stated that 99.7 percent of 1000 consecutive THAs recognised the TAL. Furthermore, the clinical result was excellent, with a dislocation rate of just 0.6%.[19]. However, in patients with inferior osteophytes, the TAL could only be identified in 31% compared to hips that don’t have inferior osteophytes. In general, TAL cannot be identified realistically as often. It can be more easily identified in low-weight and shorter individuals[46]. There is contradicting information that calls into doubt the validity of the TAL as a navigational aid. According to MRI research, the TAL's natural anteversion in healthy individuals varies; this landmark is less useful for figuring out where the cup

should be placed since it varies between 5.3° to 36.1°. Moreover, osteonecrosis, osteoarthritis and dysplasia are known to alter the hip's native acetabular position. A study examining the normal acetabular orientation in hips affected by arthritis revealed that both sexes had decreased angles of inclination and anteversion. There is no relationship between a patient's acetabular anatomy and their TAL location in cases of osteoarthritis owing to dysplasia. Pre-operative CT scans of 80 hips, those who had THA for dysplasia, revealed a range of acetabular anteversion, from 14° to 18°. Both groups' mean anteversion and range were substantially different from a control group of osteonecrosis patients. Then, this research group used TAL to guide the positioning of cups, with 39% of the cups that were implanted outside the targeted range, even though the goal was to achieve an anteversion of 15° ± 19°[47].

In a prospective RCT with 130 total hip arthroplasty patients, the obtained cup position at 3 months was evaluated by post-operative CT (THA), who were equally split between the freehand method and guided approach of acetabular component placement [48]. The research did not demonstrate a considerable improvement in inclination, but it did find significantly improved (mean) anteversion angles with navigation. Additional research supports the advantage of imageless navigation in terms of inclination. Suksathien et. al.[49] conducted a retrospective investigation whereby they compared the location of the acetabular cup on the post-operative CT scan of 31 patients of THA to 30 control cases. There were notable variations in mean anteversion and inclination. Moreover, the percentage of outliers in component placements decreased correspondingly. Remarkably, when inclination and anteversion were evaluated together, this study shows that all computer-navigated cups were within the safe zone, whereas only 48.4% of non-navigated cups were in the safe zone[49], with no significant change in the duration of surgery. Muir et al[50] stated that Computer navigation enhances cup orientation and zone adherence, thereby ensuring safety and decreasing complications of dislocation. Yet, no significant connection with better clinical results at short-term follow-up has been found. Since the imageless navigation system relies on an anterior pelvic plane to determine the position of the pelvis, it’s been criticised for its vulnerability to errors in registration and failure to consider pelvic tilt[50].

There would be inaccuracies, especially in anteversion analysis, according to an ultrasonography study that evaluated fat and skin thickness across three reference locations. This is especially troublesome for people who are fat[22]. This impact has been demonstrated by Wolf et al.[51], who found that erroneous APP registration leads to mispositioning of the acetabular components. The question of the dependability of APP was also raised by many authors. Three months after computer-navigated THA, a study by Barbier et al.[52] used a 3D-pelvic imaging equipment to evaluate 44 participants in a single-centered prospective study. Discrepancies between operational navigation data and postoperative imaging were found to be significant. To be more specific, the mean anteversion before surgery was 20.9 degrees, whereas it was 29.5 degrees after surgery. This suggests that operative anteversion had the lowest positive correlation in imageless navigation referencing APP. It is thought that the inter-observer variance during the

procedure, as well as the challenge of recording APP before surgery, is the cause of this difference[53]. The total effects of misregistering the bony landmarks have been examined by Deep and Picard[54], who in their study have also produced charts that show the potential error in cup placement. Conversely, we would argue that such inaccuracy should be implausible, particularly when conducted by skilled orthopaedic surgeons, given the wide error ranges reported (between 1 and 4 cm). Some institutions have resorted to invasive measures due to concerns of inaccurate registrations. Piercing the skin using the bony landmarks was the method used by Dorr et al.[55]. However, donor site morbidity is a concern, though unreported, increased potential for fracture, bleeding, infection, and difficulty in mobilization are not insignificant.

Further research by Lin et al.[56] revealed the limitations of navigation. Postoperative CT scans were performed on a cohort of 50 patients to determine the cup's location relative to Lewinneck's safe zones; the sample included equal computer-navigated THA patients and those who were done with the freehand technique (control). According to their statistics, navigation was better; in fact, all of the cups ended up in the target zone, but just 92% of the cups in the control group were in the safe zone[47]. The CT scans taken after the operation differed significantly from the intra-operative navigation data. Despite a minimal 0º +/-2.8º difference in absolute terms between operating inclination and radiological inclination on CT, the researchers found a significant isolated anteversion differential of 3.4º +/- 3.6º. This may be explained by the challenge of accurately documenting the APP's bony markers before surgery, as well as the idea that extremes in pelvic tilt may have an impact on the relationship between acetabular anatomy and APP[57]. Although APP is determinable, pelvic tilt is not static. Dorr et al[55] demonstrated how pelvic tilt affects the ultimate anteversion assessed after surgery; a change of 0.8° in acetabular anteversion was associated with every 1° shift in ventral-to-dorsal tilt. Ignoring the variance in spinopelvic Alignment might result in the issues mentioned earlier, such as edge loading, wear, instability, and dislocation. Thus, to avoid the complications associated with misplacement of the cup, it is crucial to assess the functional pelvic plane (FPP) to identify the normal and abnormal spinopelvic rhythm and consequently the individual native acetabular orientation.

11. CONCLUSION

The acetabular cup demands accuracy and precise arithmetics with its placement, owing to numerous complications, early failure and revision rates. With leaving surgeons divided in their opinion to conclude a best “safe zone”, it becomes more ambiguous to arrive at a definitive norm. Thus, the search with the aid of newer technologies evolves incessantly. Among each method discussed, computer-assisted navigation and robotics has strong literature evidence of advantage over other methods, as it allows us to tailor the approach and better comprehend the individual offsets in every subject yet needs robust research to prove its cost-effectiveness and long-term benefits to the patients. Thus, with available literature, we conclude, with the intention of minimizing

complications, it is obligatory to identify and individualise the functional acetabular orientation and to avail the technological support, which shall strongly impact the function and durability of total hip arthroplasty there upon the outcome and patient satisfaction as well.

Acknowledgment

We acknowledge our mentors, supporting staff, librarian, and the subject for their valuable time and willingness to publish this report.

References

1. Solovieva, S., Kontio, T., & Viikari-Juntura, E. (2018). Occupation, Physical Workload Factors, and Disability Retirement as a Result of Hip Osteoarthritis in Finland, 2005-2013. *The Journal of rheumatology*, *45*(4), 555–562. https://doi.org/10.3899/jrheum.170748.
2. Shichman, I., Roof, M., Askew, N., Nherera, L., Rozell, J. C., Seyler, T. M., & Schwarzkopf, R. (2023). Projections and Epidemiology of Primary Hip and Knee Arthroplasty in Medicare Patients to 2040-2060. *JB & JS open access*, *8*(1), e22.00112. https://doi.org/10.2106/JBJS.OA.22.00112.
3. Weber, M., Craiovan, B., Woerner, M. L., Schwarz, T., Grifka, J., & Renkawitz, T. F. (2018). Predictors of Outcome After Primary Total Joint Replacement. *The Journal of arthroplasty*, *33*(2), 431–435. https://doi.org/10.1016/j.arth.2017.08.044.
4. Danoff, J. R., Bobman, J. T., Cunn, G., Murtaugh, T., Gorroochurn, P., Geller, J. A., & Macaulay, W. (2016). Redefining the Acetabular Component Safe Zone for Posterior Approach Total Hip Arthroplasty. *The Journal of arthroplasty*, *31*(2), 506–511. https://doi.org/10.1016/j.arth.2015.09.010.
5. Bota, N. C., Nistor, D. V., Caterev, S., & Todor, A. (2021). Historical overview of hip arthroplasty: From humble beginnings to a high-tech future. *Orthopedic reviews*, *13*(1), 8773. https://doi.org/10.4081/or.2021.8773
6. Lewinnek, G. E., Lewis, J. L., Tarr, R., Compere, C. L., & Zimmerman, J. R. (1978). Dislocations after total hip-replacement arthroplasties. *The Journal of bone and joint surgery. American volume*, *60*(2), 217–220..
7. Daines, B. K., & Dennis, D. A. (2012). The importance of acetabular component position in total hip arthroplasty. *The Orthopedic clinics of North America*, *43*(5), e23–e34.https://doi.org/10.1016/j.ocl.2012.08.002.
8. Weber, M., Woerner, M., Craiovan, B., Voellner, F., Worlicek, M., Springorum, H. R., Grifka, J., & Renkawitz, T. (2016). Current standard rules of combined anteversion prevent prosthetic impingement but ignore osseous contact in total hip arthroplasty. *International orthopaedics*, *40*(12), 2495–2504. https://doi.org/10.1007/s00264-016-3171-x.

9. Dora, C., Houweling, M., Koch, P., & Sierra, R. J. (2007). Iliopsoas impingement after total hip replacement: the results of non-operative management, tenotomy or acetabular revision. *The Journal of bone and joint surgery. British volume*, *89*(8), 1031–1035. https://doi.org/10.1302/0301-620X.89B8.19208.
10. Patil, S., Bergula, A., Chen, P. C., Colwell, C. W., Jr, & D'Lima, D. D. (2003). Polyethylene wear and acetabular component orientation. *The Journal of bone and joint surgery. American volume*, *85-A Suppl 4*, 56–63. https://doi.org/10.2106/00004623-200300004-00007.
11. Widmer, K. H., & Zurfluh, B. (2004). Compliant positioning of total hip components for optimal range of motion. *Journal of orthopaedic research : official publication of the Orthopaedic Research Society*, *22*(4), 815–821. https://doi.org/10.1016/j.orthres.2003.11.001.
12. Leichtle, U. G., Leichtle, C. I., Taslaci, F., Reize, P., & Wünschel, M. (2013). Dislocation after total hip arthroplasty: risk factors and treatment options. *Acta orthopaedica et traumatologica turcica*, *47*(2), 96–103. https://doi.org/10.3944/aott.2013.2978.
13. McLawhorn, A. S., Sculco, P. K., Weeks, K. D., Nam, D., & Mayman, D. J. (2015). Targeting a New Safe Zone: A Step in the Development of Patient-Specific Component Positioning for Total Hip Arthroplasty. *American journal of orthopedics (Belle Mead, N.J.)*, *44*(6), 270–276.
14. Opperer, M., Lee, Y. Y., Nally, F., Blanes Perez, A., Goudarz-Mehdikhani, K., & Gonzalez Della Valle, A. (2016). A critical analysis of radiographic factors in patients who develop dislocation after elective primary total hip arthroplasty. *International orthopaedics*, *40*(4), 703–708. https://doi.org/10.1007/s00264-015-3022-1.
15. Naito, Y., Hasegawa, M., Tone, S., Wakabayashi, H., & Sudo, A. (2021). The accuracy of acetabular cup placement in primary total hip arthroplasty using an image-free navigation system. *BMC musculoskeletal disorders*, *22*(1), 1016. https://doi.org/10.1186/s12891-021-04902-5.
16. Lass R, Kubista B, Olischar B, Frantal S, Windhager R, Giurea A. Total hip arthroplasty using imageless computer-assisted hip navigation: a prospective randomized study. *J Arthroplast.* 2014;**29**:786–791. doi: 10.1016/j.arth.2013.08.020.
17. Tetsunaga, T., Yamada, K., Tetsunaga, T., Furumatsu, T., Sanki, T., Kawamura, Y., & Ozaki, T. (2021). Comparison of the accuracy of CT- and accelerometer-based navigation systems for cup orientation in total hip arthroplasty. *Hip international : the journal of clinical and experimental research on hip pathology and therapy*, *31*(5), 603–608. https://doi.org/10.1177/1120700020904940.
18. Weber, M., von Kunow, F., Innmann, M., Meyer, M., Thieme, M., Jerabek, S., & Renkawitz, T. (2022). Which Safe Zone Is Safe in Total Hip Arthroplasty? The Effect of Bony Impingement. *Journal of personalized medicine*, *12*(5), 812. https://doi.org/10.3390/jpm12050812.
19. Archbold, H. A., Mockford, B., Molloy, D., McConway, J., Ogonda, L., & Beverland, D. (2006). The transverse acetabular ligament: an aid to orientation of the acetabular component during primary total hip replacement: a preliminary study of 1000 cases investigating postoperative stability. *The Journal of bone and joint surgery. British volume*, *88*(7), 883–886. https://doi.org/10.1302/0301-620X.88B7.17577

20. Molho, D. A., Kuether, J. P., & Rubin, L. E. (2022). Anatomic Navigation Using the Transverse Acetabular Ligament for Acetabular Component Positioning in Total Hip Arthroplasty Through the Direct Anterior Approach. *The Journal of the American Academy of Orthopaedic Surgeons*, *30*(3), 100–103. https://doi.org/10.5435/JAAOS-D-20-00839.
21. Kelley TC, Swank ML. Role of navigation in total hip arthroplasty. J Bone Joint Surg 2009;91A:153-8.
22. Davenport, D., & Kavarthapu, V. (2016). Computer navigation of the acetabular component in total hip arthroplasty: a narrative review. *EFORT open reviews*, *1*(7), 279–285. https://doi.org/10.1302/2058-5241.1.000050.
23. Idrissi, M. E., Elibrahimi, A., Shimi, M., & Elmrini, A. (2016). Acetabular component orientation in total hip arthroplasty: The role of acetabular transverse ligament. *Acta ortopedica brasileira*, *24*(5), 267–269. https://doi.org/10.1590/1413-785220162405158405.
24. Biedermann, R., Tonin, A., Krismer, M., Rachbauer, F., Eibl, G., & Stöckl, B. (2005). Reducing the risk of dislocation after total hip arthroplasty: the effect of orientation of the acetabular component. *The Journal of bone and joint surgery. British volume*, *87*(6), 762–769. https://doi.org/10.1302/0301-620X.87B6.14745.
25. Digioia, A. M., 3rd, Jaramaz, B., Plakseychuk, A. Y., Moody, J. E., Jr, Nikou, C., Labarca, R. S., Levison, T. J., & Picard, F. (2002). Comparison of a mechanical acetabular alignment guide with computer placement of the socket. *The Journal of arthroplasty*, *17*(3), 359–364. https://doi.org/10.1054/arth.2002.30411.
26. Habor, J., Fischer, M. C. M., Tokunaga, K., Okamoto, M., & Radermacher, K. (2021). The Patient-Specific Combined Target Zone for Morpho-Functional Planning of Total Hip Arthroplasty. *Journal of personalized medicine*, *11*(8), 817. https://doi.org/10.3390/jpm11080817.
27. Tannast, M., Murphy, S. B., Langlotz, F., Anderson, S. E., & Siebenrock, K. A. (2006). Estimation of pelvic tilt on anteroposterior X-rays--a comparison of six parameters. *Skeletal radiology*, *35*(3), 149–155. https://doi.org/10.1007/s00256-005-0050-8.
28. Boettner, F., Zingg, M., Emara, A. K., Waldstein, W., Faschingbauer, M., & Kasparek, M. F. (2017). The Accuracy of Acetabular Component Position Using a Novel Method to Determine Anteversion. *The Journal of arthroplasty*, *32*(4), 1180–1185. https://doi.org/10.1016/j.arth.2016.10.004.
29. Danaei, B., & McPhee, J. (2022). Model-Based Acetabular Cup Orientation Optimization Based on Minimizing the Risk of Edge-Loading and Implant Impingement Following Total Hip Arthroplasty. *Journal of biomechanical engineering*, *144*(11), 111008. https://doi.org/10.1115/1.4054866.
30. Zingg, M., Boudabbous, S., Hannouche, D., Montet, X., & Boettner, F. (2017). Standardized fluoroscopy-based technique to measure intraoperative cup anteversion. *Journal of orthopaedic research : official publication of the Orthopaedic Research Society*, *35*(10), 2307–2312. https://doi.org/10.1002/jor.23514.
31. Schwarz, T., Weber, M., Wörner, M., Renkawitz, T., Grifka, J., & Craiovan, B. (2017). Central X-ray beam correction of radiographic acetabular cup measurement after THA: an experimental study. *International journal of computer assisted radiology and surgery*, *12*(5), 829–837. https://doi.org/10.1007/s11548-016-1489-x.

32. DeJesus, J., 4th, Nishioka, S., Andrews, S. N., Mathews, K., & Nakasone, C. K. (2023). Improved hip symmetry with an adjustable fluoroscopic grid during total hip arthroplasty. *Hip international : the journal of clinical and experimental research on hip pathology and therapy*, *33*(4), 598–603. https://doi.org/10.1177/11207000221089274.
33. Mishra, A., Verma, T., Rajkumar, Agarwal, G., Sharma, A., & Maini, L. (2020). 3D Printed Patient-Specific Acetabular Jig for Cup Placement in Total Hip Arthroplasty. *Indian journal of orthopaedics*, *54*(2), 174–180. https://doi.org/10.1007/s43465-020-00061-2.
34. Constantinescu, D. S., Costello, J. P., 2nd, Dalling, A. D., Wagner, J. D., Al-Hardan, W., & Carvajal, J. A. (2022). The efficacy of patient specific instrumentation (PSI) in total hip arthroplasty (THA): A systematic review and meta-analysis. *Journal of orthopaedics*, *34*, 404–413. https://doi.org/10.1016/j.jor.2022.10.001.
35. Tanino, H., Nishida, Y., Mitsutake, R., & Ito, H. (2021). Accuracy of a portable accelerometer-based navigation system for cup placement and intraoperative leg length measurement in total hip arthroplasty: a cross-sectional study. *BMC musculoskeletal disorders*, *22*(1), 299. https://doi.org/10.1186/s12891-021-04167-y.
36. Sotereanos, N. G., Miller, M. C., Smith, B., Hube, R., Sewecke, J. J., & Wohlrab, D. (2006). Using intraoperative pelvic landmarks for acetabular component placement in total hip arthroplasty. *The Journal of arthroplasty*, *21*(6), 832–840. https://doi.org/10.1016/j.arth.2005.12.001.
37. Meermans, G., Grammatopoulos, G., Innmann, M., & Beverland, D. (2022). Cup placement in primary total hip arthroplasty: how to get it right without navigation or robotics. *EFORT open reviews*, *7*(6), 365–374. https://doi.org/10.1530/EOR-22-0025.
38. Frandsen, J. J., Kahn, T. L., Anderson, L. A., Pelt, C. E., Peters, C. L., & Gililland, J. M. (2021). Managing Hip-Spine Concepts in the Direct Anterior Approach With Use of Fluoroscopy. *The Journal of arthroplasty*, *36*(7S), S104–S110. https://doi.org/10.1016/j.arth.2021.01.007.
39. Hamilton, W. G., Parks, N. L., McDonald, J. F., 3rd, & Pfefferle, K. J. (2019). A Prospective, Randomized Study of Surgical Positioning Software Shows Improved Cup Placement in Total Hip Arthroplasty. *Orthopedics*, *42*(1), 42–47. https://doi.org/10.3928/01477447-20190103-02.
40. Rueckl, K., Alcaide, D. J., Springer, B., Rueckl, S., Kasparek, M. F., & Boettner, F. (2019). Intraoperative measurement of cup inclination using fluoroscopy requires a correction factor. *Archives of orthopaedic and trauma surgery*, *139*(11), 1511–1517. https://doi.org/10.1007/s00402-019-03168-w.
41. Chen, A. F., Kazarian, G. S., Jessop, G. W., & Makhdom, A. (2018). Robotic Technology in Orthopaedic Surgery. *The Journal of bone and joint surgery. American volume*, *100*(22), 1984–1992. https://doi.org/10.2106/JBJS.17.01397.
42. Tsai, T. Y., Dimitriou, D., Li, J. S., & Kwon, Y. M. (2016). Does haptic robot-assisted total hip arthroplasty better restore native acetabular and femoral anatomy?. *The international journal of medical robotics + computer assisted surgery : MRCAS*, *12*(2), 288–295. https://doi.org/10.1002/rcs.1663.

43. Tanino, H., Nishida, Y., Mitsutake, R., & Ito, H. (2020). Portable Accelerometer-Based Navigation System for Cup Placement of Total Hip Arthroplasty: A Prospective, Randomized, Controlled Study. *The Journal of arthroplasty*, *35*(1), 172–177. https://doi.org/10.1016/j.arth.2019.08.044.
44. Manzotti, A., Cerveri, P., De Momi, E., Pullen, C., & Confalonieri, N. (2011). Does computer-assisted surgery benefit leg length restoration in total hip replacement? Navigation versus conventional freehand. *International orthopaedics*, *35*(1), 19–24. https://doi.org/10.1007/s00264-009-0903-1.
45. Hassan, D. M., Johnston, G. H., Dust, W. N., Watson, L. G., & Cassidy, D. (1995). Radiographic calculation of anteversion in acetabular prostheses. *The Journal of arthroplasty*, *10*(3), 369–372. https://doi.org/10.1016/s0883-5403(05)80187-1.
46. Epstein, N. J., Woolson, S. T., & Giori, N. J. (2011). Acetabular component positioning using the transverse acetabular ligament: can you find it and does it help?. *Clinical orthopaedics and related research*, *469*(2), 412–416. https://doi.org/10.1007/s11999-010-1523-1.
47. Fukui, T., Fukunishi, S., Nishio, S., Fujihara, Y., Shohei, O., & Yoshiya, S. (2013). Assessment of acetabulum anteversion aligned with the transverse acetabulum ligament: cadaveric study using image-free navigation system. *Orthopedic reviews*, *5*(1), e5. https://doi.org/10.4081/or.2013.e5.
48. Bruce-Brand, R., Magill, P., O'Neill, C., Karayiannis, P., Hill, J., & Beverland, D. (2021). Mechanical and Anatomical Alignment Guide Techniques Are Superior to Freehand in Achieving Target Orientation of an Acetabular Component. *Arthroplasty today*, *11*, 222–228. https://doi.org/10.1016/j.artd.2021.08.016.
49. Suksathien, Y., Suksathien, R., & Chaiwirattana, P. (2014). Acetabular cup placement in navigated and non-navigated total hip arthroplasty (THA): results of two consecutive series using a cementless short stem. *Journal of the Medical Association of Thailand = Chotmaihet thangphaet*, *97*(6), 629–634..
50. Muir, J. M., Foley, K. A., Fiaes, K., Wagler, J. B., Galaszewicz, M., Benson, J. R., & Bradley, M. P. (2021). Validation of a Novel Software Measurement Tool for Total Hip Arthroplasty. *Cureus*, *13*(6), e15544. https://doi.org/10.7759/cureus.15544.
51. Wolf, A., DiGioia, A. M., 3rd, Mor, A. B., & Jaramaz, B. (2005). A kinematic model for calculating cup alignment error during total hip arthroplasty. *Journal of biomechanics*, *38*(11), 2257–2265. https://doi.org/10.1016/j.jbiomech.2004.09.033.
52. Barbier, O., Skalli, W., Mainard, L., Mainard, D., & Computer Assisted Orthopedic Surgery–France (CAOS-France) (2014). The reliability of the anterior pelvic plane for computer navigated acetabular component placement during total hip arthroplasty: prospective study with the EOS imaging system. *Orthopaedics & traumatology, surgery & research : OTSR*, *100*(6 Suppl), S287–S291. https://doi.org/10.1016/j.otsr.2014.07.003.
53. Kalteis, T., Handel, M., Herold, T., Perlick, L., Paetzel, C., & Grifka, J. (2006). Position of the acetabular cup -- accuracy of radiographic calculation compared to CT-based measurement. *European journal of radiology*, *58*(2), 294–300. https://doi.org/10.1016/j.ejrad.2005.10.003.

54. Deep, K., Shankar, S., & Mahendra, A. (2017). Computer assisted navigation in total knee and hip arthroplasty. *SICOT-J*, *3*, 50. https://doi.org/10.1051/sicotj/2017034.
55. Dorr, L. D., Hishiki, Y., Wan, Z., Newton, D., & Yun, A. (2005). Development of imageless computer navigation for acetabular component position in total hip replacement. *The Iowa orthopaedic journal*, *25*, 1–9.
56. Lin, F., Lim, D., Wixson, R. L., Milos, S., Hendrix, R. W., & Makhsous, M. (2011). Limitations of imageless computer-assisted navigation for total hip arthroplasty. *The Journal of arthroplasty*, *26*(4), 596–605. https://doi.org/10.1016/j.arth.2010.05.027.
57. Steppacher, S. D., Kowal, J. H., & Murphy, S. B. (2011). Improving cup positioning using a mechanical navigation instrument. *Clinical orthopaedics and related research*, *469*(2), 423–428. https://doi.org/10.1007/s11999-010-1553-8.

Authors

Ram Sudhan Subramaniyan is a member of Indian Orthopaedic Association (IOA)and a specialist in Arthroplasty and Sports surgery and works as Associate professor of Orthopaedics in PK DAS Institute of Medical Sciences -Hospital and Medical College, Vaniamkulam, Ottapalam. Kerala 679522, India. Email: sudhansubramaniam@gmail.com

Muhammed Faisal is a member of Indian Orthopaedic Association (IOA) and Kerala Orthopaedic Association and works as a consultant in IQRAA International Hospital and Research Centre, Wayanad Road, Malaparamba, Kozhikode, Kerala, 673009

Abdul Gafoor PM is a member of Indian Orthopaedic Association (IOA) and Kerala Orthopaedic Association, and he is a fellow of Foot and Ankle surgery and presently working as a consultant in IQRAA International Hospital and Research Centre, Wayanad Road, Malaparamba, Kozhikode, Kerala, 673009

Muhammed Fazil V V is a member of Kerala Orthopaedic Association and Indian Orthopaedic Association (IOA) and works as a consultant in IQRAA International Hospital and Research Centre, Wayanad Road, Malaparamba, Kozhikode, Kerala, 673009

Anwar Marthya Hamid is a member of Indian Orthopaedic Association (IOA) and Kerala Orthopaedic Association and is a specialist sports surgeon and presently work as head of department of orthopaedics in IQRAA International Hospital and Research Centre, Wayanad Road, Malaparamba, Kozhikode, Kerala, 673009

Sharat Balemane is a member of Indian Orthopaedic Association (IOA) and a specialist in Arthroplasty and Sports Surgery and works as Associate Professor of Orthopaedics in Yenepoya Medical college Hospital, Deralakatte, Karnataka,575018, India.

Fardeen Shariff is a member of Indian Orthopaedic Association (IOA) and a specialist in Trauma and Arthroplasty, and works as Associate Professor of Orthopaedics in Yenepoya Medical College Hospital, Deralakatte, Karnataka 575018, India