

## An interesting case of PIP joint fracture of Index finger

Boris Matev, Omiros Kongorozis<sup>(✉)</sup>, Boyan Hristov, Nia Gecheva

Specialized Orthopedic University Hospital "Prof. Boycho Boychev", Sofia, Bulgaria

[omiroskongorozis@gmail.com](mailto:omiroskongorozis@gmail.com)

[doi: 10.58542/jbota.v6i03.128](https://doi.org/10.58542/jbota.v6i03.128)

**Abstract** – The Proximal Interphalangeal (PIP) joint of the index finger is a delicate structure that requires specialized treatment in the event of injury or fracture. Arthroplasty of the PIP joint in the index finger is often discouraged due to concerns over implant durability and stability, which can be compromised by the forces exerted during PIP range of motion (ROM) and pinch grip activities. Silicone devices, while commonly used, often lack rotational stability. The primary challenges associated with PIP joint injuries are the risk of permanent deformity and stiffness.

This case report presents an example of the mistreatment of a PIP joint fracture in the index finger and outlines the correct management approach based on the latest literature recommendations.

**Keywords** – PIP joint fracture, index finger, endoprosthesis

### 1. Introduction

Injuries to the PIP joint are better referred to a hand surgeon to avoid potential complications. Correct initial diagnosis is of utmost importance in choosing the most successful treatment plan. The main problem in treating these injuries is to avoid permanent deformity and stiffness. Arthroplasty of the PIP joint of index finger is often discouraged due to concerns over implant longevity and stability secondary to coronal forces this digit is exposed to during pinch<sup>1,2,3</sup>. Arthrodesis is usually the preferred choice of treatment.

### 2. Clinical Case

A 64yo female patient had a low-energy fall on February 2023 resulting in dorsal fracture-dislocation of the PIP joint in the index finger of her left hand. She was treated with closed reduction and splint for 3 months. The closed reduction resulted in misa-

lignment and volar fracture of the PIP joint. The patient complaint of edema and continuous pain. After a month she had a surgery with endoprosthesis, RegJoint type. Upon the 3<sup>rd</sup> week post-operation, radial clinodactyly and palmar flexion at the PIP joint could be noticed. She was complaining of pain, loss of function with inability to flex or extend her PIP joint of index finger of her left hand and edema. Five months after her operation, the pain started radiating from the medial side of the index finger towards the dorsal side of the wrist. A year later after her initial injury she decided to have a revision surgery in Specialized Orthopedic University Hospital "Prof.B.Boychev". The patient presented to us with 50 degrees radial deviation and 54 degrees constant flexion of her PIP joint of index finger and subsequent oedema (Fig.1,2,3,4,). An elective surgery was scheduled and performed. Realignment and arthrodesis of the PIP joint was performed by placing a plate with 4 screws (Fig.5,6). A follow-up was scheduled on 21.03.2024 where adequate bone healing was observed on Xray imaging (Fig.7,8).

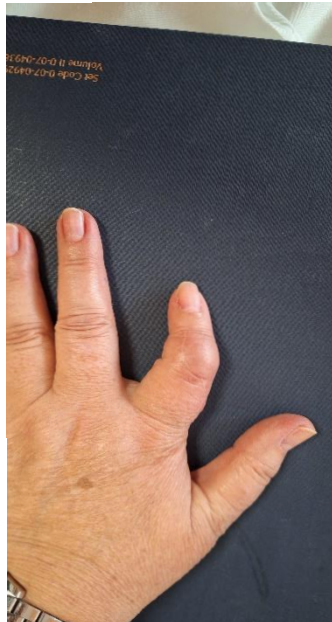


Fig.1: Patient presentation after reg joint implant

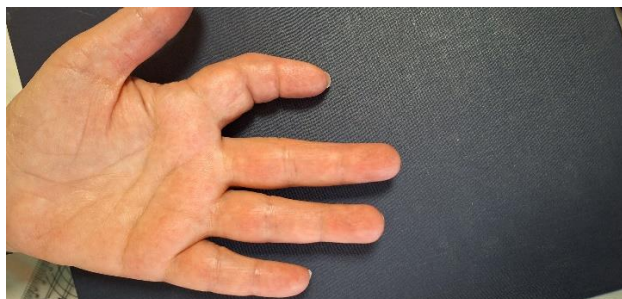

Fig.2: Patient presentation after reg joint implant

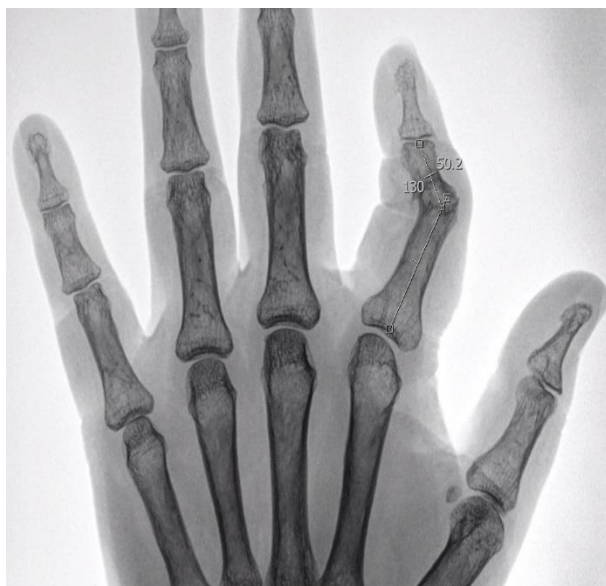

Fig.3 Xray displaying degrees of radial deviation

Article— An interesting case of PIP joint fracture of Index finger

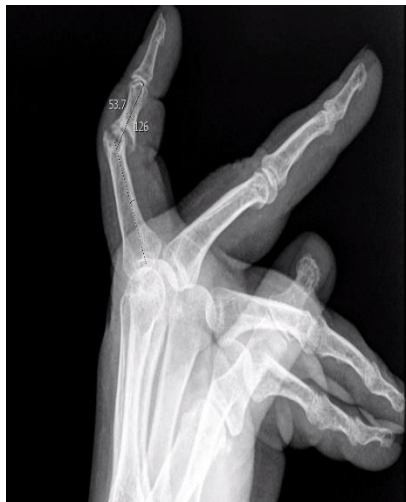

Fig.4 Xray displaying degrees of constant flexion

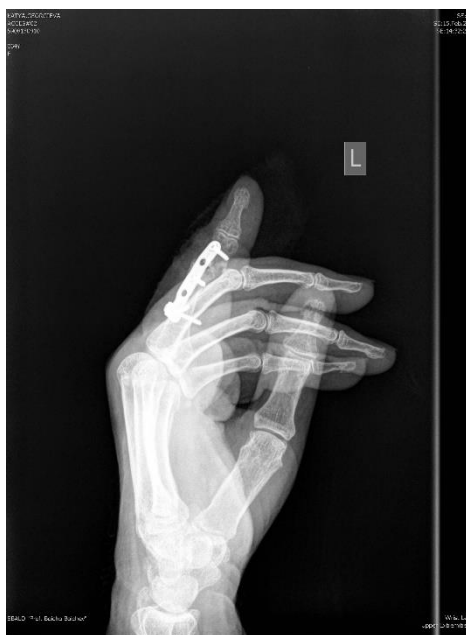

Fig.5 post-op Xray with plate fixation - PIP arthrodesis (Lateral view) - 15.02.2024

Article— An interesting case of PIP joint fracture of Index finger

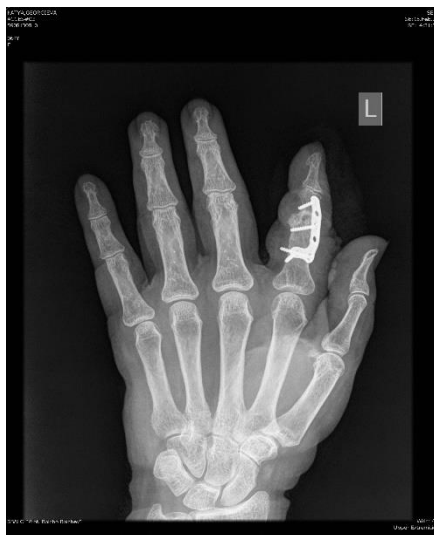

Fig.6 post-op Xray with plate fixation – PIP arthrodesis (AP view) - 15.02.20

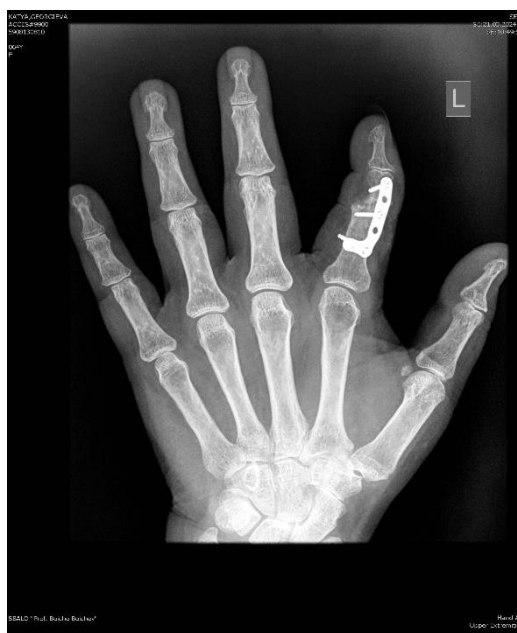

Fig.7 follow-up after 35 days (AP view)- 21.03.2024

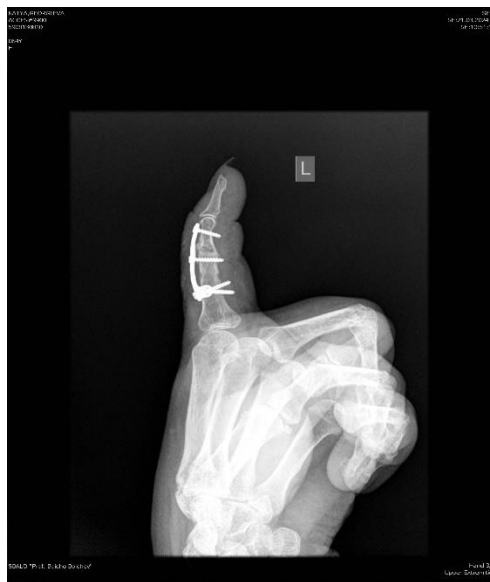

Fig.8 follow-up after 35 days (Lateral view)- 21.03.2024

### 3. Discussion

The PIP joint of index finger is a structure of importance in each individual due to its high functional capabilities and most important hand grip. An experienced hand surgeon should always be consulted and handle these delicate structures. Swanson quoted that endoprosthesis of the PIP of the index finger is not recommended<sup>1</sup>. Arthroplasty of the PIP joint of the finger is characterised by increased risk of complication in patients undergoing arthroplasty versus arthrodesis<sup>5</sup>. Additionally, there is a risk for endoprosthesis sublocation, because PIP to the index finger is a very vulnerable joint. In this case, we used plate fixation. For PIP joints we needed real joint endoprosthesis. We can't use spacer or a bioabsorbable type of implant. Also we should be very careful about protecting the neurovascular bundles and extensor mechanisms<sup>6</sup>. For performing this kind of surgery we must have an experienced hand surgeon, a proper endoprosthesis and a respected hand unit. Finally, the most important point is to have a clear and accurate indication for operation.

### 4. References

1. Swanson, D., B. Flexible implant resection arthroplasty in the hand and extremities. Mosby Co, Saint Louis, 1973.
2. Milone MT, Klifto CS, Hacquebord JH. Prosthetic Arthroplasty of Proximal Interphalangeal Joints for Treatment of Osteoarthritis and Posttraumatic Arthritis: Systematic

Review and Meta-Analysis Comparing the Three Ulnar Digits with the Index Finger. *Hand (N Y)*. 2019 Sep;14(5):658-663. doi: 10.1177/1558944718791186. Epub 2018 Aug 2. PMID: 30070590; PMCID: PMC6759965.

3. Freeland\*\*, Alan E. et al. "Proximal Interphalangeal Joint Arthrodesis." (1986).
4. Wagner, Eric R. et al. "Results of proximal interphalangeal arthroplasty: border digits versus middle digits." *Journal of Hand Surgery (European Volume)* 45 (2020): 709 - 714.
5. Vitale, Mark A. et al. "Prosthetic Arthroplasty versus Arthrodesis for Osteoarthritis and Posttraumatic Arthritis of the Index Finger Proximal Interphalangeal Joint." *The Journal of hand surgery* 40 10 (2015): 1937-48.
6. Kovachev M., V. Kovachev. Early treatment of traumatic lesions of brachial plexus in adult. *Ortho-trauma*, 2010, 4.

## Authors

**Boris Matev** is Associate professor at Medical University – Sofia. He is working in the Orthopedic Hospital „prof. Boycho Boychev“. Member of International, European and Bulgarian society for hand surgery.

**Omiros Kongorozis** is an intern doctor and works as a medical assistant at University Orthopedic Hospital „prof. Boycho Boychev“.

**Boyan Hristov** Chief assistant professor at Medical University – Sofia. He is working in the Orthopedic Hospital „prof. Boycho Boychev“. Member of International, European and Bulgarian society for hand surgery.

**Nia Gecheva** is Assistant professor at Medical University – Sofia. Resident doctor at University Orthopedic Hospital „prof. Boycho Boychev“.