

SURGICAL TECHNIQUE FOR ANATOMICAL RECONSTRUCTION OF THE DISTAL RADIOULNAR LIGAMENTS IN CHRONIC TRAUMATIC INJURY OF THE TRIANGULAR FIBROCARTILAGE COMPLEX

Nikola Simeonov^(✉), Kalin Angelov, Iliyana Marcheva, Elena Apostolu, Margarita Kateva

UMHAT "Sofiamed" - Clinic for orthopedics, traumatology, hand surgery and reconstructive surgery, Sofia, Bulgaria
nikk_simeonov@abv.bg

[DOI: 10.58542/jbota.v61i02.101](https://doi.org/10.58542/jbota.v61i02.101)

Abstract-Injury to the triangular fibrocartilage complex (TFCC) can lead to instability of the distal radioulnar joint (DRUJ). In this article, we have presented a treatment method for patients with chronic traumatic TFCC injury. The surgical technique described here demonstrates anatomical reconstruction of the volar and dorsal distal radioulnar ligament using an autologous palmaris longus tendon graft. In the period 2014-2023, 22 patients with chronic traumatic injury to the triangular fibrocartilage complex, leading to instability of the DRUJ, were operated on in our clinic. The main parameters studied pre- and post-operatively were: degree of pain during active movements in the wrist joint and prono-supination of the forearm, range of active movements in the same joints, stability of DRUJ and grip strength relative to the contralateral limb. All 22 patients reported pain reduction with active wrist movements and forearm prono-supination. This surgical technique with anatomically based reconstruction of the distal volar and dorsal radioulnar ligament provides restoration of stability of the distal radioulnar joint and reduction of pain in patients with chronic injury to the triangular fibrocartilage complex.

Key words: - triangular fibrocartilage complex, DRUJ instability, ligamentous reconstruction

1. Introduction

The skeletal architecture of the distal radioulnar joint (DRUJ) provides minimal stability, as the sigmoid fossa of the radius is shallow and its curvature is 50% greater than that of the ulnar head¹. Because of its incongruent articulation, the distal radioulnar joint

relies heavily on the surrounding soft tissues for stability. The triangular fibrocartilaginous complex (TFCC) is generally accepted as the primary soft tissue stabilizer of the distal radioulnar joint, of which the volar and dorsal radioulnar ligaments are the primary components. The triangular fibrocartilaginous complex contains three components: the articular disc, the superficial and deep radioulnar ligaments, and the ulnolunate and ulnotriquetral ligaments. Secondary stabilizers of the distal radio-ulnar joint include the tendon sheath of the tendon of m. extensor carpi ulnaris (ECU), the distal part of the interosseous membrane and m.pronator quadratus. The triangular fibrocartilaginous complex, in turn, contains deep fibers that attach to the base of the processus styloideus of the ulna along with the ulnocapitate ligament, and its superficial fibers attach to the tip and middle part of the processus styloideus of the ulna along with the ulnotriquetral ligament.

The foveal insertion of the deep fibers of the TFCC contributes more to the stability of the distal radioulnar joint due to its closer relationship with the rotational axis of the forearm.

Therefore, fractures of the apex of the processus styloideus of the ulna with disruption of only the distal components of the TFCC will not result in instability of the distal radioulnar joint.

In isolated posttraumatic DRUJ instability, the most common cause is a traumatic moment involving a fall onto an outstretched arm or forced wrist rotation, which is followed by wrist swelling with ulnar carpal joint pain aggravated by forearm pronosupination and active wrist movements. Pain at rest and swelling usually improve with time, but pain with active movement persists and may be associated with symptoms of mechanical instability, including grip weakness and the presence of a click in the joint.

Palmer proposed a classification system for TFCC injuries that divided them into traumatic and degenerative². In this article, we focus on the treatment of chronic traumatic injuries to the TFCC. In our opinion, radioulnar ligament reconstruction offers the best opportunity for anatomic reconstruction of the TFCC and restoration of normal primary stability and kinematics of the distal radioulnar joint.

2. Method

In the period 2014-2023, 22 patients with chronic traumatic injury to the triangular fibrocartilage complex, leading to instability of the DRUJ, were operated on in our clinic. The main parameters studied pre- and post-operatively were: degree of pain during active movements in the wrist joint and pronosupination of the forearm, volume of active movements in the same joints, stability of DRUJ and grip strength relative to the contralateral limb.

Operative technique: The interval between the 5th and 6th extensor compartment is reached through a dorso-ulnar approach of the wrist joint (fig. 1).

Article— Surgical technique for anatomical reconstruction of the distal radioulnar ligaments in chronic traumatic injury of the triangular fibrocartilage complex

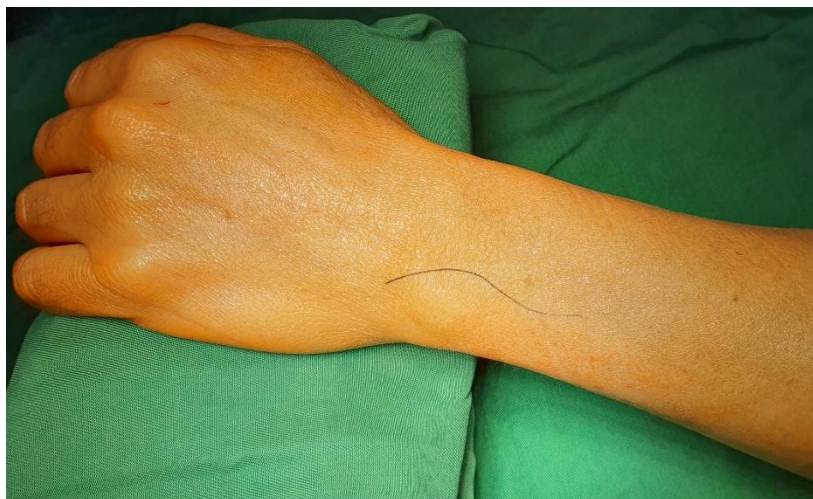

Fig.1 Lazy S dorsal access to the DRUJ between the 5th and 6th osteofibrous canals

The 5th osteofibrous canal is opened and the tendon of the extensor digiti minimi is outlined. The DRUJ is reached by advancing an L-shaped ulnar-based flap from the joint capsule of the DRUJ(fig.2) and debridement of all injured and fibrotic tissue(fig. 3).

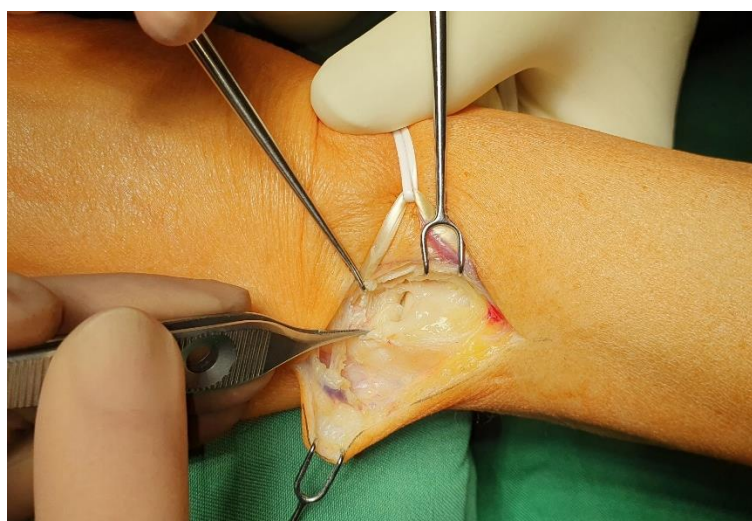


Fig. 2 Exposure of DRUJ after L-shaped capsulotomy

Article— Surgical technique for anatomical reconstruction of the distal radioulnar ligaments in chronic traumatic injury of the triangular fibrocartilage complex

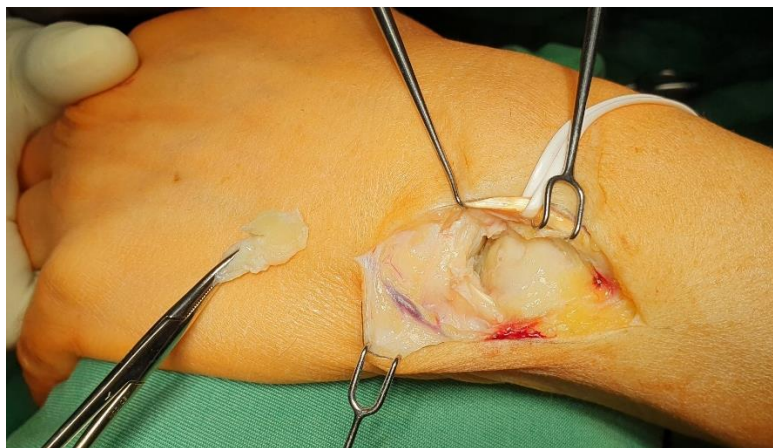


Fig. 3 Debridement of fibrous tissues in the area of the TFCC

The 4th osteofibrous canal is elevated subperiosteally. It continues with the formation of a bony canal in the radius a few millimeters proximal to the lunate fossa and 5 mm radial to the articulating surface of the sigmoid fossa. This is followed by the formation of a bony tunnel that starts at the neck of the ulna and exits at the base of the styloid of the ulna, where the deep fibers of the triangular fibrocartilage complex are captured. The bone tunnel is formed with a width according to the thickness of the tendon graft. Our preferred tendon graft is the palmaris longus tendon. In cases where m. palmaris longus is missing, a tendinous band is cut off from m. flexor carpi radialis.

The tendon graft is passed through the bony tunnel of the radius, with its volar and dorsal arms directed to the fovea of the ulna following the direction of the radioulnar ligaments (fig. 4), where both arms are placed through the bony tunnel of the ulna and brought ulnarly to the neck of the ulna (fig. 5), where it is fixed to the ulna via an anchor, after repositioning the distal radioulnar joint (fig. 6).

Article— Surgical technique for anatomical reconstruction of the distal radioulnar ligaments in chronic traumatic injury of the triangular fibrocartilage complex

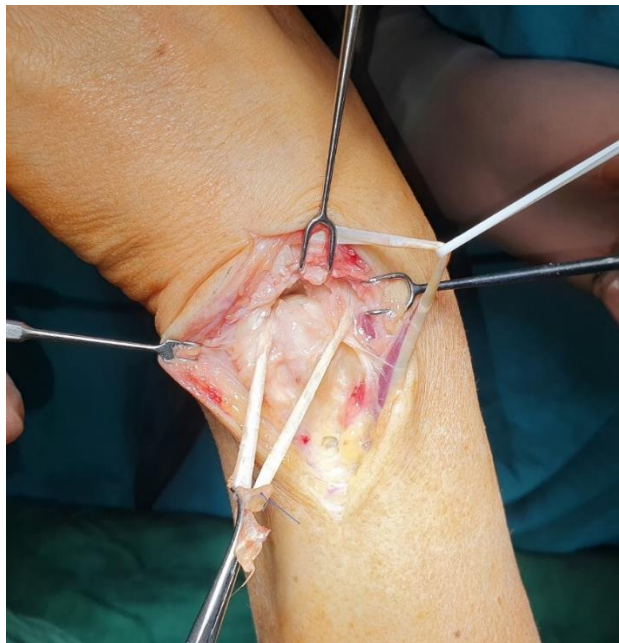

Fig. 4 Position of the tendon graft through the bone tunnel in the radius

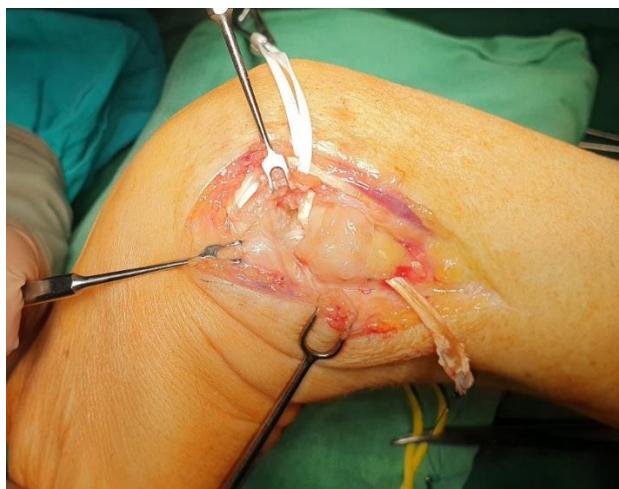

Fig. 5 Placement of a tendon graft through the bone tunnel in the ulna and tensioned to stabilize the DRUJ

Article— Surgical technique for anatomical reconstruction of the distal radioulnar ligaments in chronic traumatic injury of the triangular fibrocartilage complex

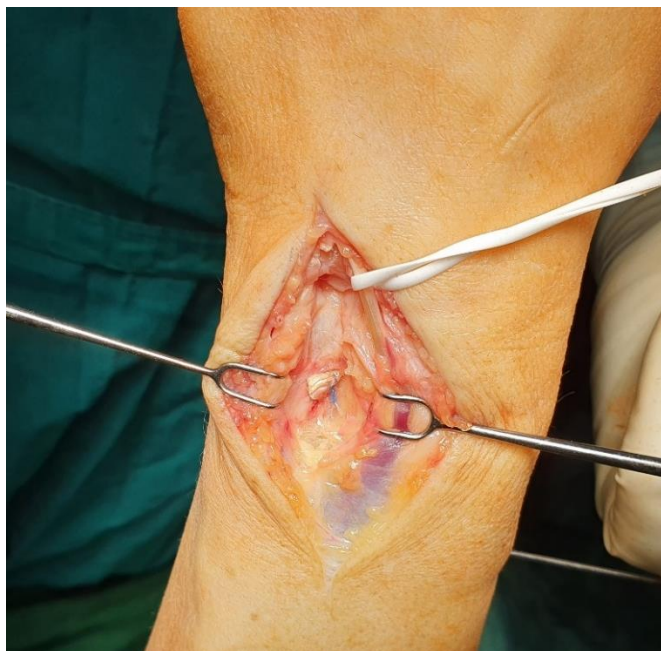

Fig. 6 Fixation of the tendon graft to the ulna using an anchor

Alternatively, the two arms can be passed in opposite directions and around the neck of the ulna, then sutured together. Regarding the stability of the fixation, Georgi Ganchev found the highest percentage of stability and strength of tendon graft attachment by anchor, followed by end-to-end tendon suture and finally resorbable screw attachment³.

For the first 6 weeks, pronosupination is blocked with a K-needle and a volar cast. At week 8, the splint is removed and full active range of motion is encouraged. The patient is recommended not to perform heavy physical efforts before 3 months after the operation.

3. Results

All 22 patients reported pain reduction with active wrist movements and forearm pronosupination. Postoperatively, the average wrist range of motion was extension 75°, flexion 70°, supination 75°, and pronation 85° (fig. 7).

Article— Surgical technique for anatomical reconstruction of the distal radioulnar ligaments in chronic traumatic injury of the triangular fibrocartilage complex

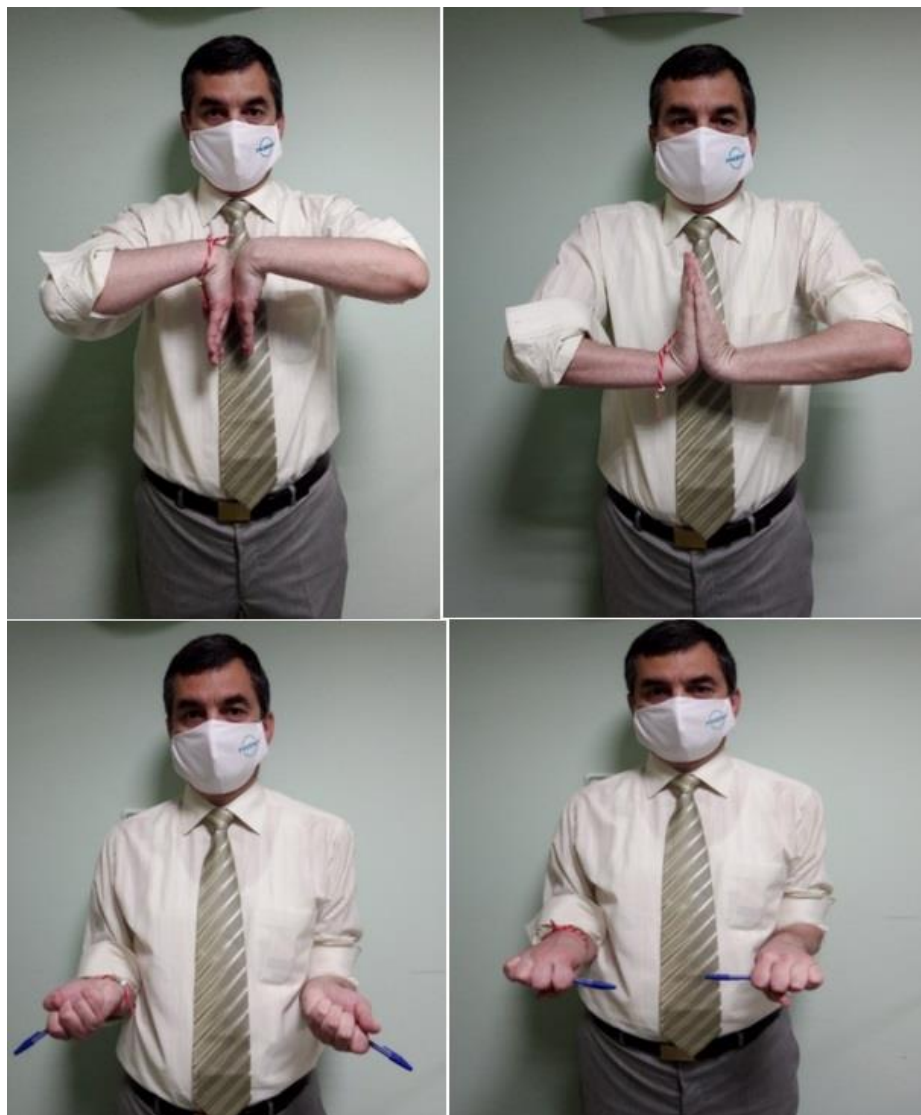

Fig.7 Functional result 4 years postoperatively

All but one patient who underwent distal radioulnar ligament reconstruction showed clinically improved and restored stability of the radioulnar joint. The grip strength of the operated limb is 85% of the grip strength of the contralateral upper limb.

4. Discussion

The main indication for distal radioulnar ligament reconstruction is instability of the distal radioulnar joint with irreparable injury to the triangular fibrocartilage complex. DRUJ instability can coexist with other causes of ulnar wrist pain, including m.ECU tendon subluxation, ulnar carpal impingement syndrome, and DRUJ arthritis. These conditions, among others, should be considered in the differential diagnosis plan in order to clarify the painful symptomatology before determining DRUJ instability as a leading factor. If instability occurs due to poor union in distal radius fractures, ligamentous reconstruction can be performed along with a corrective osteotomy of the radius. In fact, any significant bony deformation should be corrected before resorting to ligamentous reconstruction in order to restore stability to the DRUJ.

Ligament reconstruction of DRUJ is contraindicated in the presence of already advanced arthrosis of the joint. Distal radioulnar ligament reconstruction offers the best opportunity to restore normal primary stability and kinematics of the distal radioulnar joint. Although if we consider that one of the ligaments provides dominant stability of the DRUJ in a particular position of the forearm in supination or pronation, then the other ligament provides secondary stability. Which in itself leads us to think that both the volar and dorsal radioulnar ligaments must be injured for complete joint luxation to occur^{4,5}. Therefore, reconstruction of both ligaments will provide optimal restoration of normal kinematics of the distal radioulnar joint.

There are many described methods for DRUJ reconstruction: capsular plication; non-anatomic tendon stabilizations with the m.ECU tendon, dynamic muscle transfer and reconstruction of the sigmoid fossa of the radius^{6,7,8}. These surgical interventions do not restore the normal anatomy of the joint and thus cannot be a reliable method to restore the normal function of the DRUJ, and may lead to limitation of active movements in the joint itself^{9,10}.

Adams-Berger reconstruction aims to connect the distal radius and ulna using a tendon graft that mimics the native anatomic sites of TFCC insertions, thereby restoring normal joint kinematics. This makes this operative technique the preferred method for restoring the function and stability of DRUJ.

5. Conclusion

This surgical technique with anatomically based reconstruction of the distal volar and dorsal radioulnar ligament provides restoration of stability of the distal radioulnar joint and reduction of pain in patients with chronic injury to the triangular fibrocartilage complex.

6. References

1. Af Ekenstam F, Hagert CG. Anatomical studies on the geometry and stability of the distal radioulnar joint. *Scand J Plast Reconstr Surg* 1985; 19 (1): 17–25.

Article— Surgical technique for anatomical reconstruction of the distal radioulnar ligaments in chronic traumatic injury of the triangular fibrocartilage complex

2. Palmer A K. Triangular fibrocartilage complex lesions: a classification. *J Hand Surg Am.* 1989;14(04):594–606
3. Георги Ганчев. Посттравматична нестабилност на дисталната радио-улнарна става. Диагностични трудности и терапевтичен подход 2017; стр.71
4. Kihara H, Short WH, Werner FW, Fortino MD, Palmer AK. The stabilizing mechanism of the distal radioulnar joint during pronation and supination. *J Hand Surg [Am]* 1995;20(6):930–6
5. Ward LD, Ambrose CG, Masson MV, Levaro F. The role of the distal radioulnar ligaments, interosseous membrane, and joint capsule in distal radioulnar joint stability. *J Hand Surg [Am]* 2000;25(2):341–512
6. Adams BD, Divelbiss BJ. Reconstruction of the posttraumatic unstable distal radioulnar joint. *Orthop Clin North Am* 2001;32 (02):353–363
7. Adams BD, Lawler E. Chronic instability of the distal radioulnar joint. *J Am Acad Orthop Surg* 2007;15(09):571–575
8. Johnston K, Durand D, Hildebrand KA. Chronic volar distal radioulnar joint instability: joint capsular plication to restore function. *Can J Surg* 2009;52(02):112–118
9. Seo KN, Park MJ, Kang HJ. Anatomic reconstruction of the distal radioulnar ligament for posttraumatic distal radioulnar joint instability. *Clin Orthop Surg* 2009;1(03):138–145
10. Petersen MS, Adams BD. Biomechanical evaluation of distal radioulnar reconstructions. *J Hand Surg [Am]* 1993;18(2):328–34

7. Authors

Nikola Simeonov is secretary general of Society for Surgery of the Hand-Bulgaria. He works as an orthopedics and traumatology resident at Clinic for orthopedics, traumatology, hand surgery and reconstructive surgery UMHAT “Sofiamed”- Sofia, Bulgaria.

Kalin Angelov is a member of the Bulgarian Orthopedic and Traumatology Association (BOTA) and member of Society for Surgery of the Hand-Bulgaria. He works as an orthopedics surgeon and hand surgeon at Clinic for orthopedics, traumatology, hand surgery and reconstructive surgery UMHAT “Sofiamed”- Sofia, Bulgaria.

Iliyana Marcheva is a member of Society for Surgery of the Hand-Bulgaria. She works as hand surgeon at Clinic for orthopedics, traumatology, hand surgery and reconstructive surgery UMHAT “Sofiamed”- Sofia, Bulgaria.

Elena Apostolu is a member of Society for Surgery of the Hand-Bulgaria. She works as hand surgeon at Clinic for orthopedics, traumatology, hand surgery and reconstructive surgery UMHAT “Sofiamed”- Sofia, Bulgaria.

Margarita Kateva is a president of Society for Surgery of the Hand-Bulgaria. She is head of Clinic for hand surgery and reconstructive surgery UMHAT “Sofiamed”- Sofia, Bulgaria.